

T-Lymphoblastic Lymphoma with an Unusual t(8;14)(q24;q11) – Case Report

Inga Mandac¹, Slobodanka Ostojić Kolonić^{1,4}, Radovan Vrhovac^{1,4}, Ružica Lasan-Trčić²,
Jasminka Jakelić-Piteša³ and Ika Kardum-Skelin^{1,4}

¹ University Hospital »Mercur«, Zagreb, Croatia

² University Hospital Center Zagreb, Zagreb, Croatia

³ University Hospital Center Split, Split, Croatia

⁴ University of Zagreb, School of Medicine, Zagreb, Croatia

ABSTRACT

Cytogenetic abnormalities seen at presentation of acute lymphoblastic leukemia or lymphoblastic lymphoma (ALL/LBL) are associated with distinct clinical and hematologic disease entities. T-ALL/LBL are morphologically indistinguishable from those of B-ALL/LBL. An abnormal karyotype is found in 50–70% of cases of T-ALL/LBL. We present a 35-year old male patient with T-ALL/LBL and t(8;14)(q24;q11.2). Our patient presented with B-symptoms, bulky mediastinal disease and CNS infiltration. Bone marrow was morphologically normal and cytogenetically without clonal aberrations. Cytological findings of the supraclavicular lymph node showed numerous CD3 positive (100%) and CD2 positive (88%) lymphoblasts, negative for CD34 and CD10. Flow cytometry of lymph node revealed T cell phenotype of immature cells: CD45+CD2+CD5+CD7+CD4+CD8+CD3cyt +CD3TdT+CD10-CD34-HLAD/DR-. Cytogenetic analysis of lymph node showed translocation t(1;4)(p32;p12), t(8;14)(q24;q11.2). Southern blot analysis of extracted DNA from the supraclavicular lymph node demonstrated clonal rearrangement of the T cell antigen receptor (TCR/J) gene (region Vb+Jb2). Based on these findings, diagnosis of T lymphoblastic non Hodgkin lymphoma was established. Cerebrospinal fluid analysis showed CNS infiltration with 49% lymphoblasts positive for CD4 and CD8. The disease progressed rapidly with poor response to therapy. T-ALL/LBL with an unusual t(8;14)(q24;q11.2) is a very rare hematologic disorder with rapid disease progression and poor response to conventional therapy because of frequent central nervous system involvement and early relapses.

Key words: T-lymphoblastic lymphoma, cytogenetics, t(8;14)(q24;q11.2)

Introduction

The term »lymphoblastic lymphoma« was recognized first in 1905 by Sternberg who reported a case of malignant lymphoma involving the mediastinum which terminated in acute leukemia¹. T-lymphoblastic lymphoma (T-LBL) is a rare subtype of adult high-grade non-Hodgkin lymphoma (NHL) with an incidence of approximately 2%. Lymphoblastic lymphoma (LBL) and acute lymphoblastic leukemia (ALL) have been grouped together into a single entity in the new WHO classification of hematologic malignancies^{2,12}. Even though, lymphoblasts are precursors of T or B lymphocytes, approximately 85–90% of lymphoblastic lymphomas (LBL) in adults are of T-cell phenotype; morphologic, immunophenotypical and molecular similar to ALL. In some previous studies, the clin-

ical distinction between LBL and ALL has varied and most centers have used the degree of bone marrow infiltration or the presence of leukemic involvement of the peripheral blood to determine a cut-off between these entities (patients with more than 25% bone marrow involvement are generally classified as T-ALL)^{2,4}.

Cytological and histological features of LBL and ALL are very similar^{2,3}. In smears, the cells are of medium size with a high nuclear/cytoplasmic ratio; there may be a considerable size range from small lymphoblasts with very condensed nuclear chromatin and no evident nucleoli to larger blasts with finely dispersed chromatin and relatively prominent nucleoli. The number of mitotic fig-

ures is reported to be higher in T-ALL than B-ALL. T lymphoblasts frequently show focal acid phosphatase activity in smear and imprint preparations, though it is not specific.

Typical flow cytometric findings for B-lymphoblastic lymphoma are as follows: CD19⁺, CD10 bright, CD20^{+/-}, CD22^{+/-}, TdT⁺, HLA-DR⁺, CD34^{+/-}, slg⁻. Findings for T-lymphoblastic lymphoma are as follows: sCD3⁻, but CD3⁺, CD4⁺/CD8⁺ or CD4⁻ CD8⁻, CD2^{+/-}, CD5^{+/-}, CD7^{+/-}, TdT⁺, CD34^{+/-}, CD10^{+/-}^{3,4}.

Clinical and biological features of T-LBL such as male predominance (adults between 20 to 40 years), high incidence of mediastinal tumor, and other lymphomatous manifestations are similar to those of T-ALL and different from B-LBL, often with bone marrow and central nervous system involvement⁴.

T-ALL and T-LBL are separated by an arbitrary margin of 25% bone marrow involvement; patients with higher degree of bone marrow infiltration are generally classified as T-ALL. As far as treatment is concerned, a similar approach is used both for T-ALL and T-LBL. It is now widely accepted that LBL and ALL represent different manifestations of the same disease⁴.

Cytogenetic studies on acute lymphoblastic leukemias have led to the identification of recurrent abnormalities specific to ALL, and abnormalities which are independent prognostic factors⁵. A variety of chromosomal translocations can occur in T-cell acute lymphoblastic lymphoma/leukemia.

We describe a case of 35-year old male with T-lymphoblastic Non Hodgkin lymphoma and an unusual finding of t(8;14)(q24;q11.2).

Case Report

A 35 year old male was admitted to our Hematology Department in November 2008.

Three weeks before admission he noticed raised body temperature, night sweats, skin itching, pain in left shoulder and weakness of his left arm and a week later, cough, chest pain and dyspnea. Patient was then referred to a regional medical center for imaging studies.

CT scan of the chest showed expansive mass in anterior and middle mediastinum. In view of these imaging studies, the patient was referred to a tertiary care center for further work up.

Transbronchial cytology of mediastinal mass showed non-Hodgkin's lymphoma-cells. Upon arrival, peripheral cervical, supraclavicular and axillar lymphadenopathy was noticed. Laboratory analysis revealed normochromic normocytic anemia, elevated erythrocyte sedimentation rate (ESR), lactate dehydrogenase (LDH) and beta 2 microglobulin levels. Coombs tests were negative.

Bone marrow was morphologically normal and cytogenetically without clonal aberrations. Cytological findings of the supraclavicular lymph node (Figure 1a) showed 100% CD3 (Figure 1b) and 88% CD2 positive (Figure 1c) cells, negative for CD34 and CD10. Flow cytometric

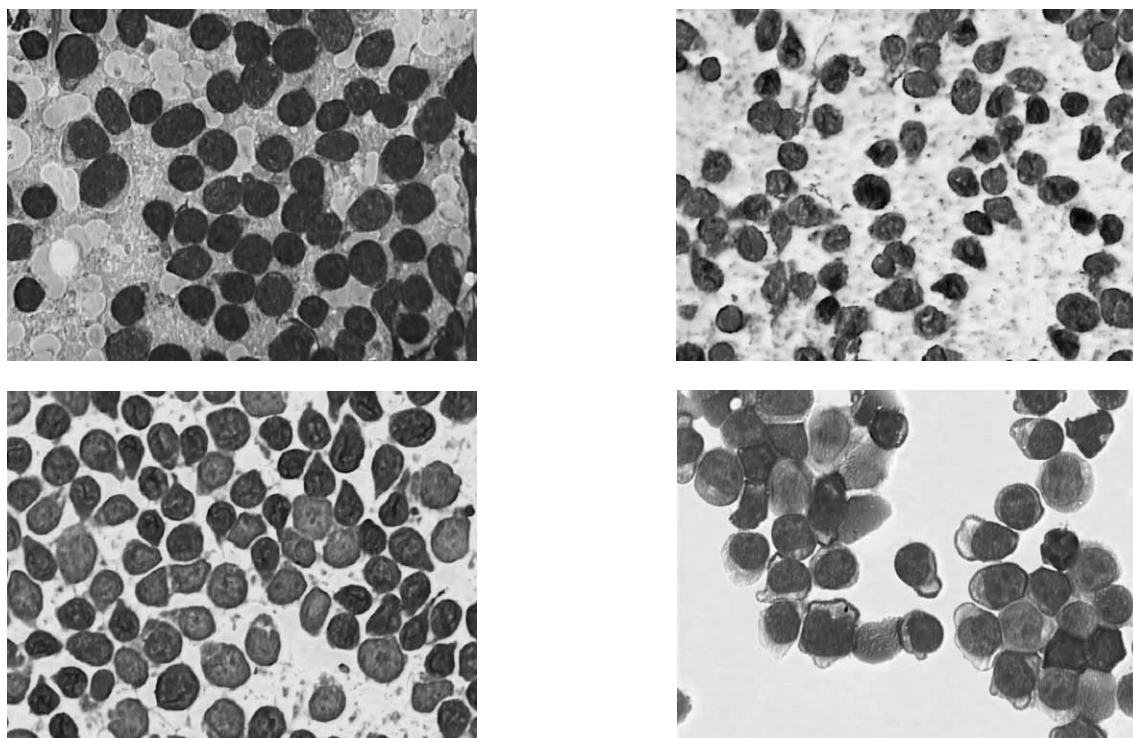


Fig. 1. T-lymphoblastic leukemia in lymph node smears: (a) May-Grünwald-Giemsa staining (b) strong CD3 and (c) CD 2 (d) immunopositivity (LSAB), and cytopsin smear of cerebrospinal fluid – May-Grünwald-Giemsa staining.

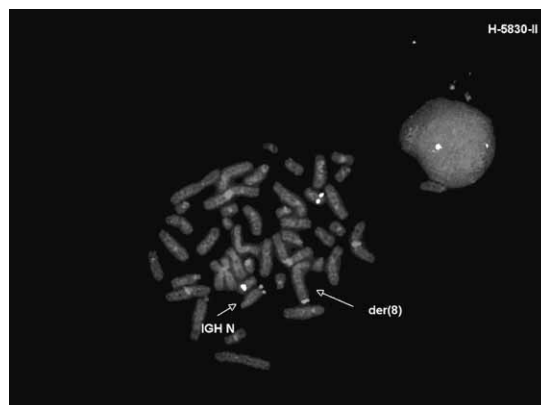
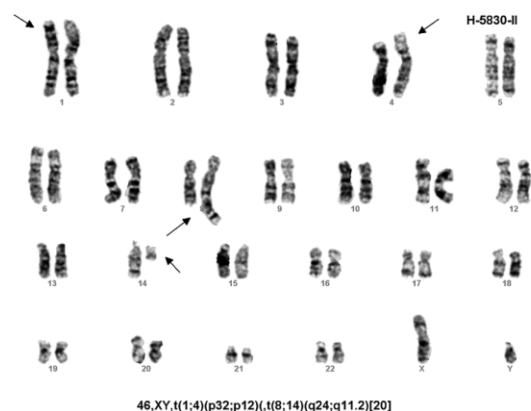

Fig. 2. Cytogenetic analysis of lymph node with t(8;14) (q24;q11,2); (a) FISH pattern and (b) detection of t(8;14).

analysis of lymph node showed T cell phenotype of immature cells: CD45+CD2+CD5+CD7+CD4+CD8+ CD3cyt+ CD3TdT+CD10-CD34-HLAD/DR-.

Conventional cytogenetic (Figure 2a) and FISH analysis (Figure 2b) of lymph node showed translocation t(1;4)(p32;p12) and t(8;14)(q24;q11.2). Southern blot analysis of extracted DNA from the supraclavicular lymph node demonstrated clonal rearrangement of the T cell antigen receptor (TCR/J) gene (region Vb+Jb2). Examination demonstrated T lymphoblastic Non Hodgkin lymphoma.

Cerebrospinal fluid analysis showed CNS infiltration with 49% lymphoblasts (Figure 1d) positive for CD4 and CD8.

An intensive multiagent chemotherapy regimen hyper-CVAD, has been administered in three courses from November 2008 until January 2009. It alternated cyclophosphamide, vincristine, doxorubicin and dexamethasone with high doses of methotrexate and cytarabine.

Supportive care apart from the usual measures for chemotherapy such as sufficient fluid uptake and antiemetic treatment included antimicrobial prophylaxis with a quinolone (500 mg ciprofloxacin twice daily) and antifungal prophylaxis with 200 mg fluconazole daily. Appropriate transfusion support was provided. Packed red blood cells were given for symptomatic anemia or at hemoglobin levels below 75 g/L and platelet transfusions were administered prophylactically for platelet counts lower than $5 \times 10^9/L$ or therapeutically if clinically indicated. Neutropenic febrile episodes generally resulted in an initiation of broad spectrum parenteral antibiotics. Filgrastim (600 mcg daily) was initiated approximately 24 hours after completion of intensive courses of chemotherapy until absolute neutrophil count (ANC) was higher than $1 \times 10^9/L$.

Peripheral facial paresis occurred in February 2009 during pancytopenia following third cycle of Hyper-CVAD. Diagnostic workup showed regression of the mediastinal mass, but CNS infiltration was still present.

A new line of intensive chemotherapy with cyclophosphamide, etoposide and clofarabine was administered to-

gether with cranial irradiation (2500cGy/8x). Disease remission has been achieved, with complete regression of mediastinal infiltrates, clearance of lymphoblasts from cerebrospinal fluid, normal peripheral blood smear and marrow biopsy.

Stem cell transplantation from a matched relative donor has been considered, but no donor was found. In March 2009, the patient presented with painful left testicular swelling. Physical examination was otherwise unremarkable. Testicular cytology revealed lymphoblastic infiltration. A chemotherapy regimen containing fludarabine, cyclophosphamide and dexamethasone (FED) was administered without success. He was admitted in May with hyperleucocytosis (more than $100 \times 10^9/L$ leukocytes, 70% of atypical blasts) and died soon thereafter.

Discussion

T cell malignancies are divided into two major groups: precursor T cell lymphoblastic neoplasms, derived from maturing thymocytes and peripheral T cell lymphomas (PTCL) arising from mature post-thymic T cells. PTCL, altogether accounting for less than 15% of all NHL, comprise a number of entities. According to the clinical presentation of the disease they are classified as disseminated, predominantly extranodal or cutaneous or predominantly nodal. In comparison with B-cell malignancies, T-cell neoplasms are overall characterized by an inferior treatment outcome. Because of the characteristic properties of this group of malignancies, both cytologically and immunologically, a diagnosis of lymphoblastic lymphoma or leukemia could be made with virtual certainty^{6,7}. The immunostaining of TdT on paraffin-embedded sections is a useful method for differentiating lymphoblastic lymphoma from other lymphomas. Terminal deoxynucleotidyl transferase (TdT) is a DNA polymerase located in the cell nucleus which catalyses the polymerization of deoxynucleotides at the 3'hydroxyl ends of oligo- or polydeoxynucleotide initiators without a template. Morphologically, T-lymphoblastic lymphoma is indistinguishable from L1 ALL^{6,7}. According to definition from new WHO

classification, T-lymphoblastic leukemia/lymphoblastic lymphoma is a neoplasm of lymphoblasts committed to the T cell lineage, typically composed of small to medium-sized blast cells with scant cytoplasm, moderately condensed to dispersed chromatin and inconspicuous nucleoli, involving bone marrow (BM) and blood (T acute lymphoblastic leukemia, T-ALL) or presenting with primary involvement of thymus, nodal or extranodal sites (T-acute lymphoblastic lymphoma, T-LBL) as defined in the French-American-British (FAB) classification of ALL¹².

Here we presented a male patient with T-ALL/LBL with t(8;14)(q24;q11) which is very rare. Prevalence is 0.5 to 1.3 % among all cases of ALL and about 2% among T-ALL.

On the molecular point of view, location of 8q24 contains gene *c-myc* which is juxtaposed with the gene of the T-cell receptor alpha chain (TCR-alpha), and location 14q11 encodes the genes for T-cell receptor alpha (TCR-alpha) and T-cell receptor delta (TCR-delta). Some studies concluded that this chromosomal translocation seems to be unique and specific for T-cell malignancy¹³. Although a sensitive marker for Burkitt lymphoma, *c-myc* rearrangements are not specific, as they are occasionally seen in lymphoblastic lymphoma, B-cell lymphoma and very aggressive transformed follicular lymphoma⁹. Cytogenetic translocation t(8;14) involving TCR-alpha and *c-myc* genes in T-cell malignancies are analogous to variant t(2;8) and t(8;12) translocations observed in Burkitt lymphoma, and they may play a role in the evolution of the leukemic process¹⁴. T-cell leukemia bearing a t(8;14)(q24;q11) translocation, potentially has *in vivo* functional cytolytic activity. It is not determined whether this activity contributes to the patient's clinical condition¹⁶.

A Pediatric Oncology Group Study from Kaleen and colleagues presented clinicopathologic findings and survival data from 10 patients with B-precursor phenotype ALL and t(8;14)(q11.2;q32). Their data showed that t(8;14) does not increase the risk of relapse with these patients¹⁰.

Lange et al. presented fifteen pediatric cases of T-cell leukemia/lymphoma with a t(8;14)(q24;q11). The estimated prevalence of this abnormality among all cases of ALL was 1%. There was male predominance, high white blood cell count (median $95 \times 10^9/L$), central nervous system infiltration, bulky extramedullary leukemia and T-cell immunophenotype¹⁶. ALL with chromosomal translocations t(8;14)(q24;q32) and less commonly its variants t(2;8)(p12;q24) or t(8;22)(q24;q11) is characterized by the morphology of blast cells, presence of monoclonal surface immunoglobulins (sIg), and these translocations lead to rearrangements of the proto-oncogene *c-myc*, located at band 8q24. It predominates in children and adolescents and is less common in adults. There is male predominance with bulky extramedullary leukemia, central nervous system infiltration and high white blood cell count. The disease progresses rapidly and response to conventional therapy is poor because of frequent central nervous system involvement and early relapses^{8,11,12}. Our patient presented with B-symptoms, bulky mediastinal

disease and CNS infiltration, very similar to previously described T-ALL.

A variety of therapeutic approaches has been reported for adult LBL generally not separating B- and T-cell type and separate results for adult T-LBL were only rarely presented.

Therapy of lymphoblastic lymphoma and T-ALL with cytogenetic abnormality t(8;14)(q24;q11) is similar to regimen used in adult ALL, including CNS prophylaxis and maintenance therapy⁴. Since LBL are a rare entity, treatment remains uncertain and many studies have been done to find suitable chemotherapy protocol. Compared to B-ALL patients, T-ALL patients have increased risk for induction failure, early relapse and isolated CNS relapse. In adult protocols, T-ALL is treated similarly to other types of ALL. Various treatment approaches have been applied to LBL in adults, including protocols for high-grade NHL such as CHOP, CHOEP, as well as different regimens used for treatment of ALL. These include the so called Hoelzer, LSA2-L2 modified, Hyper CVAD, GIMEMA LAL094, Stanford regimen, and others, as well⁴.

Hoelzer et al. demonstrated results of study with 45 adult patients with T-LBL treated according to an ALL-type regimen. The large majority of patients (91%) was younger than 50 years, reflecting the generally lower median age of T-ALL/LBL patients. A mediastinal involvement was evident in 89% of the patients which was higher than in T-ALL (63%). Clinical picture and laboratory values of T-LBL patients were different from T-ALL in several respects (near to normal peripheral blood values and rare initial CNS involvement in T-LBL). The treatment approach was similar to previously reported successful regimen in childhood T-LBL which was the strongest evidence for the high effectiveness of ALL-type chemotherapy in T-LBL¹⁷.

The focus is usually placed on drugs with particular effectiveness in T-ALL like cyclophosphamide, cytarabine, intensive use of asparaginase and methotrexate⁴.

The GMALL study will evaluate the efficacy and tolerability of treatment for adult T-lymphoblastic lymphoma (T-LBL) according to a protocol for acute lymphoblastic leukemia. Patients receive one year of intensive cyclical chemotherapy with additional prophylaxis for central nervous system (CNS) relapse by intrathecal therapy and cranial irradiation and mediastinal irradiation after induction chemotherapy⁴.

Both autologous and allogeneic transplantation with normal or reduced intensity conditioning are also often used as part of treatment strategy.

It is evident that all efforts for improvement of treatment strategies have to be made in frontline therapy since outcome of relapsed patients with T-LBL is extremely poor. This indicates the need for morphologic recognition of this malignant lymphoma regardless of the presence of nuclear convolution, age of the patient, and site of presentation.

T-lymphoblastic lymphoma and its cytogenetic variants are hematologic entities which represent a true challenge both in the diagnostic and therapeutic field. Newer diagnostic methods have enabled better characterization and recognition of this disease. Although there is no consensus regarding the optimal therapeutic ap-

proach, aggressive chemotherapy including stem cell transplantation remains the preferred and most widely used treatment strategy. Newer therapeutic modalities that could lead to better prognosis of these patients are eagerly awaited.

REFERENCES

1. NATHWANI NB, DIAMOND WL, WINBERG DC, KIM H, BEARMAN RM, GLICK JH, JONES SE, GAMS RA, NISSEN NI, RAPPAPORT H, Cancer, 9 (1981) 2347. — 2. SWEETENHAM JW, Curr Hematol Malign Rep, 1 (2006) 241. — 3. DE LEVAL L, BISIG B, THIELEN C, BONIVER J, GAULARD P, Crit Rev Oncol Hematol, 72 (2009) 125. — 4. HOELZER D, GOKBUGET N, DIGEL W, FAAK T, KNEBA M, REUTZEL R, ROMEJKO JJ, ZWOLINSKI J, WALEWSKI J, Blood, 99 (2002) 4379. — 5. PATEL KJ, SAHIBZADA UL, WANDERLEY MC, J Hematol Oncol, 2 (2009) — 5. A Collaborative Study of the Group Francais de Cytogenetique Hematologique, Blood, 87 (1996) 3135. — 6. RIZVI MA, EVENS AM, TALLMAN MS, NELSON B, ROSEN ST, Blood, 107 (2006) 1255. — 7. BOYER J, Atlas Genet Cytogenet Oncol Hematol, 3 (2001) 436. — 8. HECHT JL, ASTER C, J Clin Oncol, 18 (2000) 3707. — 9. CASTELLA A, DAVEY FR, KUREC AS, NELSON DA, Cancer, 50 (1982) 1764. — 10. KALEEM Z, SHUSTER JJ, CAROLL AJ, BOROWITZ MJ, PULLEN DJ, CAMITTA BM, ZUTTER MM, WATSON MS, Leuk, 15 (2001) 1304. — 11. BERNARD O, LARSEN CJ, HAMPE A, MAUCHAUFFE M, BERGER R, MATHIEU MAHUL D, Oncog, 2 (1988) 195. — 12. SWERDLOW S, CAMPO E, HARRIS N, JAFFE E, PILERI S, STEIN H, THIELE J, VARDIMAN J, WHO Classification of Tumours of Haematopoietic and Lymphoid Tissues, 4 (Lyon, 2008) — 13. INABA T, MURAKAMI S, OKU N, ITOH K, URA Y, NAKANISHI S, SHIMAZAKI C, NISHIO A, NAKAGAWA M, FUJITA N, Cancer Genet Cytogenet, 1 (1990) 69. — 14. MATHIEU MD, SIGAUX F, ZHU C, BERNHEIM A, MAUCHAUFFE M, DANIEL MT, BERGER R, LARSEN CJ, Int J Cancer, 38 (1986) 835. — 15. MAZIARZ RT, ARCECI RJ, BERNSTEIN SC, FRAZIER L, SMITH BR, KASAI M, TANTRAVAHI R, STROMINGER JL, Blood, 79 (1992) 1523. — 16. LANGE BJ, RAIMONDI SC, HEEREMA N, NOWELL PC, MINOWADA J, STEINHERZ PE, ARENSON EB, O'CONNOR R, SANTOLI D, Leukemia, 6 (1992) 613. — 17. REITER A, SCHRAPPE M, LUDWIG WD, Blood, 95 (2000) 416.

I. Mandac

University Hospital »Merkur«, Zajčeva 19, 10000 Zagreb, Croatia
e-mail: imandac@yahoo.com

T-LIMFOBLASTIČNI LIMFOM SA RIJETKOM TRANSLOKACIJOM t(8;14)(q24;q11) – PRIKAZ SLUČAJA

SAŽETAK

Citogenetske abnormalnosti koje se javljaju kod akutne limfoblastične leukemije ili limfoblastičnog limfoma (ALL/LBL), povezane su s različitim kliničkim i hematološkim entitetima. T-ALL/LBL je morfološki prepoznatljiv u odnosu na B-ALL/LBL. Abnormalan kariotip se može naći u 50–70% slučajeva T-ALL/LBL. Prikazujemo slučaj 35-godišnjeg bolesnika sa T-ALL/LBL i t(8;14)(q24;q11.2) koji se prezentirao B-simptomima, proširenom medijastinalnom bolesti i infiltracijom CNS-a. Koštana srž je morfološki bila normalna bez klonskih aberacija. Citologija supraklavikularnog limfnog čvora opisala je brojne CD3 pozitivne (100%) i CD2 pozitivne (88%) limfoblaste, negativne za CD34 i CD10. Protočna citometrija limfnog čvora pokazala je T-stanični fenotip nezrelih stanica: CD45+CD2+CD5+CD7+CD4+CD8+CD3cyt+CD3TdT+CD10-CD34-HLAD/DR-. Citogenetskom analizom limfnog čvora nađena je translokacija t(1;4)(p32;p12) i t(8;14)(q24;q11.2), a Southern blot analizom ekstrahirane DNA iz supraklavikularnog limfnog klonalno preuđenje TCR/J gena (regija Vb+Jb2). Postavljena je dijagnoza T-limfoblastičnog ne-Hodgkinovog limfoma. Analizom likvora nađe se infiltracija CNS-a s 49% limfoblasta pozitivnih na CD4 i CD8. Bolest je brzo napredovala, a odgovor na terapiju je bio slab. T-ALL/LBL sa neuobičajenom t(8;14)(q24;q11.2) je vrlo rijedak hematološki poremećaj s brzim napredovanjem bolesti i slabim odgovorom na standardnu terapiju, dijelom i radi česte zahvaćenosti središnjeg živčanog sustava i ranog relapsa.