



Središnja medicinska knjižnica

Judaš M., Capanec M. (2007) *Adult structure and development of the human fronto-opercular cerebral cortex (Broca's region)*. *Clinical Linguistics & Phonetics*, 21 (11-12). pp. 975-89. ISSN 0269-9206

<http://informahealthcare.com/loi/clp>

<http://dx.doi.org/10.1080/02699200701617175>

<http://medlib.mef.hr/731>

University of Zagreb Medical School Repository

<http://medlib.mef.hr/>

ADULT STRUCTURE AND DEVELOPMENT OF THE HUMAN FRONTO-
OPERCULAR CEREBRAL CORTEX (BROCA'S REGION)

Miloš Judaš (1) and Maja Ceganec (2)

(1) Croatian Institute for Brain Research, School of Medicine, University of Zagreb

(2) Developmental Neurolinguistics Lab, Department of Speech and Language Pathology,
Faculty of Education and Rehabilitation Sciences, University of Zagreb

Correspondence to:

Miloš Judaš, MD, PhD,
Professor of Neuroscience and Anatomy,
Section of Developmental Neuroscience (Head),
Department of Neuroscience,
Croatian Institute for Brain Research,
School of Medicine, University of Zagreb,
Šalata 12, 10000 Zagreb, Croatia
Phone: +385 1 4596 801
Fax: +385 1 4596 942
E-mail: mjudas@hiim.hr

ABSTRACT:

Broca's area encompasses opercular and triangular part of the inferior frontal gyrus, covered by Brodmann's areas 44 and 45, respectively. Recent neuroimaging studies have revealed that, in addition to classical language functions, Broca's area has novel and unexpected functions, serving as a likely interface of action and perception important for both verbal and nonverbal communication. In this review, we focus on structural features of Broca's area in adult and developing human brain. We emphasize that: (a) in terms of architectonic classification, Broca's area displays a dual nature by virtue of its intermediate position between agranular motor-premotor cortex and granular prefrontal associative cortex; and (b) numerous studies of morphological asymmetries are of limited value for understanding neurobiological basis of functions implemented by Broca's area. Finally, we summarize findings from our ongoing study on postnatal development of two defining cytoarchitectonic features of Broca's area in the adult brain, magnopyramidity (meaning that pyramidal neurons in layer III are larger than those in layer V) and dysgranularity (meaning that cortical layer IV is present, but poorly developed). We conclude that areal specification of areas 44 and 45 requires at least 2 (and probably 3) years of postnatal life for its gradual completion.

Introduction

It is generally accepted that, in the majority of adult humans, cortical language networks are located in the perisylvian region of the left cerebral hemisphere (Ojemann 1991, 2003; Aboitiz et al. 2006). The anterior component of these networks is located in the fronto-opercular region, i.e. opercular and triangular part of the inferior frontal gyrus. The opercular and triangular part are occupied by cytoarchitecturally defined Brodmann's areas (Brodmann, 1909) 44 and 45, respectively (figure 1A) and constitute the so-called Broca's area (or Broca's region). Early investigators conceptualized the Broca's area as an exclusive speech-production area (for review, see Ojemann 1991 and Bookheimer 2002). Indeed, Broca's area is involved in the organization of articulatory sequences and inner speech (Démonet et al. 1992), in subvocal rehearsal (Paulesu et al. 1993), in the initiation of speech (Alexander et al., 1990; Horwitz et al., 2003), in phonological processing (Démonet et al., 1992; Zatorre et al. 1996), in syntactic processing (Embick et al. 2000, Friederici et al. 2003, Heim et al. 2003) including the musical syntax (Maess et al. 2001), and in syntactical and phonological working memory (Fiebach et al. 2005). In addition, Paulesu et al. (1997) suggested that anterior (triangular) part of the Broca's area is related to lexical retrieval, whereas its posterior (opercular) part is involved in motor articulation. Broca's area is also involved in modulation of motor excitability during speech perception (Watkins and Paus, 2004) and can be activated by listening to speech (Wilson et al. 2004).

However, numerous recent neuroimaging in vivo studies have revealed that, in addition to classical language functions, the Broca's area has novel and unexpected functions (for review, see Bookheimer, 2002; Rizzolatti and Craighero 2004; Nishitani et al. 2005; Pulvermüller 2005). In fact, Broca's area seems to consist of several (partly overlapping) subsystems that are involved in various functions, such as object manipulation and grasping (Binkofski et al. 1999) imagery of motion (Binkofski et al. 2000), imitation of movements (Iacoboni et al. 1999, Heiser et al. 2003), motor preparation (Krams et al. 1998) and planning (Fincham et al. 2002). In a recent review, Nishitani et al. (2005) summarized the evidence suggesting that Broca's area serves as a likely

interface for sensory and motor sequencing (i.e., an interface of action and perception) and has a central role as an orchestrator of time-sensitive perceptual and motor functions underlying verbal and nonverbal communication. Similarly, Rizzolatti and co-workers (Rizzolatti and Arbib 1998; Rizzolatti and Craighero 2004) proposed that Broca's area controls oro-laryngeal, oro-facial and brachio-manual movements; represents the seat of mirror-neuron system; is essential for planning, observation, understanding and imitation of actions; and thus served as key neurobiological substrate for evolution of speech (Rizzolatti and Arbib 1998; Arbib 2005).

In this review, we focus on structural development of the human Broca's area. We first briefly describe the following relevant topics: (a) major cytoarchitectonic features and still unresolved problems in regional architectonic classification of areas 44 and 45 in the adult human brain; (b) morphological asymmetries of the Broca's area in the adult human brain and major confounding factors in their interpretation; (c) histological asymmetries of the adult Broca's area as revealed in studies of its overall cytoarchitectonics, total number of neurons, and analysis of specific cellular elements; and (d) available data on histological development of the human Broca's area. Finally, we use material from our ongoing study to illustrate development of two major and defining cytoarchitectonic features of the Broca's area: magnopyramidity (layer III pyramidal neurons being larger than layer V pyramidal neurons) and dysgranularity (layer IV being visible, but poorly developed).

Cytoarchitectonics of the adult human Broca's area.

There are several detailed cytoarchitectonic descriptions of Broca's area in the adult human brain (von Economo and Koskinas, 1925; Riegele, 1931; Kreht, 1936; Kononova, 1949; Amunts et al., 1999). It is generally agreed that opercular part of the inferior frontal gyrus is occupied by cytoarchitectonic area 44 (Brodmann 1909; figure 1A) or FCBm (von Economo and Koskinas 1925, figure 1B), while the triangular part is occupied by area 45 of Brodmann, i.e. area FDgamma of von Economo and Koskinas. Both areas represent a homotypical isocortex, consisting of six

cortical layers in both cyto- and myeloarchitectonic preparations (figure 2A). In addition, both areas occupy an intermediate position between agranular (motor-premotor) and granular (prefrontal associative) regions of the frontal lobe (figure 2B). Finally, two common and defining features of both area 44 and 45 are the presence of very large pyramidal neurons in layer III (magnopyramidity – figure 3A) and incomplete development of the cortical layer IV (dysgranularity – figure 3B). However, it should be noted that with respect to regional architectonic classification areas 44 and 45 have received a dual existence and that the problem remains unresolved to the present. Namely, Brodmann (1909) decided that the entire inferior frontal gyrus (including areas 44, 45 and 47) represents a unique architectonic region (figure 1C), while von Economo and Koskinas (1925) classified area 44 (their FCBm) as belonging to prerolandic region and area 45 (their FDgamma) as belonging to frontal region (figure 1D and figure 3C). That difference in regional classification of opercular and triangular area is not trivial but reflects a basic disagreement with respect to assumed evolutionary history and human-specific nature of the Broca's area. In one view (first exposed by Brodmann), Broca's area represents a human-specific part of the frontal cortex, subserving speech and language. According to another view (first exposed by von Economo and Koskinas), areas 44/FCBm and 45/FDgamma represent a specific ventrolateral part of the broad intermediate cortical zone wedged between agranular motor-premotor cortex caudally and granular prefrontal associative cortex rostrally. This intermediate position is reflected in unique combination (or mixture) of defining architectonic features which Broca's area shares with both agranular (unimodal) and granular (polymodal and supramodal) zones of the frontal cortex. Namely, Broca's area displays clearly visible but poorly developed cortical layer IV, and development of layer IV indicates its affinity with fully granular prefrontal cortex. On the other hand, Broca's area displays large pyramidal neurons in cortical layers III and V, which indicates its affinity with generally magnocellular motor-premotor cortices. In addition, some of its layer III pyramidal neurons are so prominent and larger than those in layer V, which makes Broca's area unique within the entire

frontal lobe and confers to it the designation of magnopyramidity (figure 3A). This problem of dual nature of Broca's area, in terms of structure as well in terms of function, at present remains unresolved – or, more precisely, largely ignored. On the one hand, it is now clear that African great apes and orangutans possess well defined inferior frontal gyrus with opercular and triangular parts, which are occupied by human-like areas 44 and 45 (for review see Sherwood et al., 2003). Thus, Brodmann (1909, 1912) was probably wrong when he assumed that Broca's area is human-specific part of the cerebral cortex. On the other hand, the dual nature of key components of Broca's area figure prominently in modern functional classifications of the frontal cortex. For example, Mesulam (1985) describes opercular area 44 as motor association cortex (more suited to unimodal motor processing, such as articulation and fluency) while triangular area 45 has been envisaged as a higher-order heteromodal association cortex which receives modality specific input and then performs cross-modal associations, which are requisite for performing complex linguistic functions. However, recent discoveries of novel and non-linguistic functions of the Broca's area render such dual classification very doubtful.

Morphological asymmetry of Broca's area in the adult human brain

A number of studies analyzed the existence of morphological asymmetry of Broca's area in the adult human brain. Measurements of surface area of combined opercular and triangular part of the inferior frontal gyrus suggested a leftward asymmetry in about 60-75% of human brains (Albanese et al., 1989; Falzi et al. 1982). In volumetric MRI studies, left triangular part was described as larger than the right in about 70-88% of right-handers (Foundas et al., 1995, 1996, 1998, 2001; Gauger et al., 1997; Knaus et al., 2006), but no consistent leftward asymmetry was found for opercular part of the inferior frontal gyrus (Tomaiuolo et al., 1999; Knaus et al. 2006). Harasty et al. (1997) reported that the cortical volume fraction of the Broca's area in females was 20.4% larger than in males, and a recent study (Cantalupo and Hopkins, 2001) even claimed that opercular area 44 is asymmetric (larger in the left hemisphere) in great ape brains. In sum, there is

not yet a consensus regarding morphological asymmetries of the human inferior frontal gyrus. In addition, such morphological studies are subject to serious criticisms. First, surface area measurements may not be adequate estimates of underlying tissue volume (Tomaiuolo et al., 1999). Second, cytoarchitectonic borders did not consistently coincide with sulcal contours, and therefore, macroscopic features are not reliable landmarks of cytoarchitectonic borders in human brain (Amunts et al., 1999) or in brains of great apes (Sherwood et al., 2003). Finally, grossly observable asymmetries of language-related brain areas may not offer much information to explain the unique neural wiring that supports human language, which probably evolved by reorganization of circuits within a region in the absence of dramatic volumetric change (Amunts et al., 1999; Sherwood et al. 2003). Obviously, to resolve these issues one needs microstructural studies at histological and cellular level.

Histological asymmetries of the adult Broca's area

In the early study of cytoarchitectonic asymmetry of opercular area 44, Galaburda (1980) analyzed 10 adult human brains and found a leftward asymmetry in six brains and a rightward asymmetry in one brain. However, he did not analyze the possible asymmetry of triangular area 45. In a recent study, Amunts et al. (1999) performed a detailed stereological analysis of cytoarchitecture and intersubject variability of Broca's region in the adult human brain and presented several interesting findings. First, intersubject variability in the cytoarchitecture of areas 44 and 45 was significantly greater than cytoarchitectonic differences between these areas in individual brains. Second, intersubject variability in cytoarchitecture was accompanied by intersubject variability in the positions of areas 44 and 45 relative to sulci and gyri. Third, the volumes of area 44 differed across subjects by up to a factor of 10. Fourth, area 44 but not area 45 was left-over-right asymmetrical in all brains. Namely, the left area 44 had greater volume fraction of neuropil, i.e. more space between cell bodies, occupied by synaptic connections

between neurons. This last finding implies that left area 44 (but not area 45) has an increased information processing capacity (Amunts et al. 1999).

At the cellular level, asymmetry was described for magnopyramidal neurons of area 45, but not in area 44 (Hayes and Lewis 1993, 1995). Namely, the largest (magnopyramidal) neurons in layer III had larger cross-sectional area of cell bodies in left area 45. This interhemispheric difference appeared to be a unique characteristic of the largest neurons, since the mean size of all layer III pyramidal neurons was not significantly different in the left and right area 45 (Hayes and Lewis 1993, 1995). These studies suggest that magnopyramidal layer III neurons of left area 45 are a likely population of neurons to be involved in the circuitry of language functions because layer III pyramidal neurons typically furnish associational and callosal projections (Barbas 1986). In addition, these magnopyramidal neurons may have a unique chemical phenotype as well, since they tend to be immunoreactive for nonphosphorylated neurofilament protein (Hayes and Lewis, 1993), whereas smaller pyramidal neurons of the same layer tend to be immunoreactive for calbindin (Hayes and Lewis, 1992). Surprisingly, the subsequent analysis of the total dendritic length of magnopyramidal layer III neurons in area 45 revealed no significant difference between neurons of left and right hemisphere (Hayes and Lewis, 1996). Another study of total dendritic length focused on opercular area 44 in adult human brains (Scheibel et al., 1985). Although total dendritic length was not significantly different in left and right hemisphere, an interesting finding was that a larger proportion of the length on the left side was made up of higher order (distal) dendrite branches, and lower order (proximal) segments predominated on the right (Scheibel et al., 1985). Scheibel and co-workers speculated that these findings indicate an early preponderance of dendrite growth in the right Broca's area followed by enhanced dendrite growth in the left Broca's area coincident with the beginning of conceptualization and speech function (Scheibel et al., 1985).

Development of asymmetries in the human Broca's area

There are few studies concerning the structural development of the human Broca's area, and they were mostly focused on the development of structural asymmetries. In the first stereological developmental study of total number of neurons in areas 44 and 45, Uylings et al. (2005) found that: (a) no substantial postnatal increase in total number of neurons occurred in areas 44 and 45; (b) no major asymmetry in total number of neurons in area 44 and 45 was detected; and (c) the volume of these areas reached adult values around 7 years.

Amunts et al. (2003) analyzed development of overall cytoarchitectonic asymmetry of the Broca's area and found that asymmetry was already present in 1-year-old infants, and tended to increase with age, which was significant in area 45, but not in area 44. An adult-like, leftward asymmetry in the volume fraction of cell bodies (i.e., larger volume fraction of neuropil on the left side) was reached at approximately 5 years in area 45 and 11 years in area 44 (Amunts et al. 2003). These findings are in broad agreement with findings on postnatal development of dendritic arborizations of pyramidal neurons in the Broca's area (Simonds and Scheibel 1989). These authors reported that dendrites in the right Broca's area develop more precociously than those on the left and seem more advanced during the perinatal period. Thereafter, both growth spurts and resorption seemed to occur, until dendrite systems of the left Broca's area begin to surpass those on the right by the fourth to sixth year of postnatal life. However, dendritic growth was not completed in distal dendritic segments even as late as the sixth year (Simonds and Scheibel 1989). The findings from above mentioned studies suggest that Broca's area displays prolonged postnatal development and that the interhemispheric asymmetry in the cytoarchitecture of areas 44 and 45 is a result of microstructural plasticity that continues throughout life (Amunts et al. 2003).

Postnatal development of defining architectonic features of the Broca's area

In this final section, we briefly describe major findings of our ongoing investigation on postnatal development of two defining cytoarchitectonic features of the Broca's area: magnopyramidal and dysgranularity. Namely, these two features are crucial for distinguishing areas 44 and 45 from surrounding cortical areas in the adult brain, and it is not known when during the postnatal development these features acquire their adult-like properties. Are humans born with layer III pyramidal neurons of Broca's area larger than layer V pyramidal neurons (magnopyramidal), and with dysgranular layer IV? If so, why are almost two years required for significant development of speech and language functions? Previous studies on early postnatal development of Broca's area did not provide answers to these questions, but tacitly assumed that cortex of opercular and triangular region by its topographic position represents developing areas 44 and 45, respectively.

We study cytoarchitectonic differentiation and areal specification of prospective fronto-opercular areas 44 and 45 by analyzing Nissl-stained serial sections of 35 human brains ranging in age from 8. week post conception to 15 postnatal years. The brains are part of extensive Zagreb Neuroembryological Collection, and the investigation was reviewed and approved by Institutional Review Board (Ethical Committee of the School of Medicine, University of Zagreb). The brains were obtained at autopsy from Departments of Gynecology, Pathology and Forensic Medicine of the School of Medicine in Zagreb. The brains were fixed in 4% buffered paraformaldehyde (pH 7.4), and paraffin- or celloidin-embedded blocks of left fronto-opercular region were serially sectioned in the coronal plane in 10-12 μm thick (paraffin blocks) or 25-30 μm thick (celloidin blocks) histological sections. Every 20th section was mounted on a glass slide and stained for cell bodies by cresyl violet (Nissl staining) or by silver solution (Gallyas' staining).

We found that regional architectonic differentiation of the frontal lobe cortex began during the last trimester of gestation. However, even in the full-term newborns, the fronto-opercular cortex is still quite immature and lacks defining features of individual cortical areas (figure 4). For

example, the entire frontal cortex still contains granular layer IV and displays the presence of the transient fetal subplate zone. Here, we focus on early postnatal development of magnopyramidity and dysgranularity of the Broca's area. Figures 5 to 8 display laminar development (low magnification photographs) and development of pyramidal and granular neurons in layers III, IV and V (high magnification photographs) in infants and children aged 3 months, 18 months, 3 years and 7 years.

In 3-month-old infant (figure 5), layer IV is still well-developed, and pyramidal neurons in layers III and V are of similar size and still much smaller than in later stages. In opercular region of 18-month-old child (figure 6) and in triangular region of 3-year-old child (figure 7), layer IV displays significantly decreased cell-packing density and contains scattered large pyramidal neurons (figure 6, IV). Thus, dysgranularity of Broca's area seems to be gradually established (especially in opercular area 44) from second to third postnatal year. However, note that pyramidal neurons of layers III and V are still of similar size. Although in some specimens (e.g., in 18-month-old child illustrated in figure 6) at least some pyramidal neurons of layer III seem to attain magnopyramidal appearance, there is pronounced interindividual variability at these developmental ages, so that in other specimens layer III pyramidal neurons do not appear larger than those in layer V. We suggest that magnopyramidity develops somewhat later than dysgranularity, during the second half of the second postnatal year. On the other hand, both defining architectonic features are clearly established in the Broca's area of 7-year-old child (figure 8).

As magnopyramidity and dysgranularity represent defining architectonic features for delineation of areas 44 and 45 in adult brains, our findings suggest that areal specification of these language-related areas is prolonged event which requires at least 2 years of postnatal life for its gradual completion. Furthermore, the timing of completion of areal specification of areas 44 and 45 (during the third postnatal year) roughly coincides with the onset of full-fledged speech and language development. We are currently performing a quantitative stereological analysis of

magnopyramidal and dysgranular in the fronto-opercular region in order to discern a precise onset and relative timing of these crucial architectonic parameters of the Broca's area.

Acknowledgements:

We gratefully acknowledge the technical assistance of Zdenka Cmuk, Danica Budinščak and Božica Popović in preparation of histological sections. This work was supported by Croatian Ministry of Science, Education & Sport grant no. 0108115 awarded to M.J.

References

- Aboitiz, F., García, R.R., Bosman, C., & Brunetti, E. (2006) Cortical memory mechanisms and language origins. *Brain and Language*, 98, 40-56.
- Albanese, E., Merlo, A., Albanese, A., & Gomez, E. (1989). Anterior speech region: asymmetry and weight-surface correlation. *Archives of Neurology*, 46, 307-310.
- Alexander, M.P., Naeser, M.A., & Palumbo, C. (1990). Broca's area aphasias: Aphasia after lesions including the frontal operculum. *Neurology*, 40, 353-362.
- Amunts, K., Schleicher, A., Bürgel, U., Mohlberg, H., Uylings, H.B.M., & Zilles, K. (1999). Broca's region revisited: Cytoarchitecture and intersubject variability. *Journal of Comparative Neurology*, 412, 319-341.
- Amunts, K., Schleicher, A., Ditterich, A., & Zilles, K. (2003) Broca's region: Cytoarchitectonic asymmetry and developmental changes. *Journal of Comparative Neurology*, 465, 72-89.
- Arbib, M. (2005). From monkey-like action recognition to human language. An evolutionary framework for neurolinguistics. *Behavioral and Brain Sciences*, 28, 105-167.
- Barbas, H. (1986). Pattern in the laminar origin of corticocortical connections. *Journal of Comparative Neurology*, 252, 415-422.

- Binkofski, F., Buccino, G., Stephan, K.M., Rizzolatti, G., Seitz, R.J., & Freund, H.J. (1999). A parieto-premotor network for object manipulation: evidence from neuroimaging. *Experimental Brain Research*, 128, 210-213.
- Binkofski, F., Amunts, K., Stephan, K.M., Posse, S., Schormann, T., Freund, H.J., Zilles, K., & Seitz, R.J. (2000). Broca's region subserves imagery of motion: a combined cytoarchitectonic and fMRI study. *Human Brain Mapping*, 11, 273-285.
- Bookheimer, S. (2002). Functional fMRI of language: New approaches to understanding the cortical organization of semantic processing. *Annual Review of Neuroscience*, 25, 151-188.
- Brodmann, K. (1909). *Vergleichende Lokalisationslehre der Grosshirnrinde, in ihren Prinzipien dargestellt auf Grund des Zellenbaues*. Leipzig: Johann Ambrosius Barth.
- Brodmann, K. (1912). Neue Ergebnisse über die vergleichende histologische Lokalisation der Grosshirnrinde mit besonderer Berücksichtigung des Stirnhirns. *Anatomischer Anzeiger*, 41, 157-216.
- Cantalupo, C., & Hopkins, W.D. (2001). Asymmetric Broca's area in great apes. *Nature*, 414, 505.
- Démonet, J.F., Chollet, F., Ramsay, S., Cardebat, D., Nespoulous, J.L., Wise, R., et al. (1992). The anatomy of phonological and semantic processing in normal subjects. *Brain*, 115, 1753-1768.
- Embick, D., Marantz, A., Miyashita, Y., O'Neil, W., & Sakai, K.L. (2000). A syntactic specialization for Broca's area. *Proceedings of the National Academy of Sciences of the United States of America*, 97, 6150-6154.
- Falzi, G., Perrone, P., & Vignolo, L.A. (1982). Right-left asymmetry in anterior speech region. *Archives of Neurology*, 39, 239-240.
- Fiebach, C.J., Schlesewsky, M., Lohmann, G., von Cramon, D.Y., & Friederici, A.D. (2005). Revisiting the role of Broca's area in sentence processing: Syntactic integration versus syntactic working memory. *Human Brain Mapping*, 24, 79-91.

- Fincham, J.M., Carter, C.S., van Veen, V., Stenger, V.A., & Anderson, J.R. (2002). Neural mechanisms of planning: a computational analysis using event-related fMRI. *Proceedings of the National Academy of Sciences of the United States*, 99, 3346-3351.
- Foundas, A.L., Leonard, C.M., & Heilman, K.M. (1995). Morphologic cerebral asymmetries and handedness. The pars triangularis and planum temporale. *Archives of Neurology*, 52, 501-508.
- Foundas, A.L., Leonard, C.M., Gilmore, R.L., Fennell, E.B., & Heilman, K.M. (1996). Pars triangularis asymmetry and language dominance. *Proceedings of the National Academy of Sciences of the United States*, 93, 719-722.
- Foundas, A.L., Eure, K.F., Luevano, L.F., & Weinberger, D.R. (1998). MRI Asymmetries of Broca's area: the pars triangularis and pars opercularis. *Brain and Language*, 64, 282-296.
- Foundas, A.L., Weisberg, A., Browning, C.A., & Weinberger, D.R. (2001). Morphology of the frontal operculum: A volumetric magnetic resonance imaging study of the pars triangularis. *Journal of Neuroimaging*, 11, 153-159.
- Friederici, A.D., Rüschemeyer, S.A., Hane, A., & Fiebach, C.J. (2003). The role of left inferior frontal and superior temporal cortex in sentence comprehension: localizing syntactic and semantic processes. *Cerebral Cortex*, 13, 170-177.
- Galaburda, A.M. (1980). La région de Broca: observations anatomiques faites un siècle après la mort de son découvreur. *Revue Neurologique*, 136, 609-616.
- Gauger, L.M., Lombardino, L.J., & Leonard, C.M. (1997). Brain morphology in children with specific language impairment. *Journal of Speech, Language, and Hearing Research*, 40, 1272-1284.
- Harasty, J., Double, K.L., Halliday, G.M., Kril, J.J., & McRitchie, D.A. (1997). Language-associated cortical regions are proportionally larger in the female brain. *Archives of Neurology*, 54, 171-176.
- Hayes, T.L., & Lewis, D.A. (1992) Nonphosphorylated neurofilament protein and calbindin immunoreactivity in layer III pyramidal neurons of human neocortex. *Cerebral Cortex*, 2, 56-67.

Hayes, T.L., & Lewis, D.A. (1993). Hemispheric differences in layer III pyramidal neurons of the anterior language area. *Archives of Neurology*, 50, 501-505.

Hayes, T.L., & Lewis, D.A. (1995). Anatomical specialization of the anterior motor speech area: hemispheric differences in magnopyramidal neurons. *Brain and Language*, 49, 289-308.

Hayes, T.L., & Lewis, D.A. (1996). Magnopyramidal neurons in the anterior motor speech region. Dendritic features and interhemispheric comparisons. *Archives of Neurology*, 53, 1277-1283.

Heim, S., Opitz, B., & Friederici, A.D. (2003). Distributed cortical networks for syntax processing: Broca's area as the common denominator. *Brain and Language*, 85, 402-408.

Heiser, M., Iacoboni, M., Maeda, F., Marcus, J., & Mazziotta, J.C. (2003). The essential role of Broca's area in imitation. *European Journal of Neuroscience*, 17, 1123-1128.

Horwitz, B., Amunts, K., Bhattacharyya, R., Patkin, D., Jeffries, K., Zilles, K., & Braun, A.R. (2003). Activation of Broca's area during the production of spoken and signed language: a combined cytoarchitectonic mapping and PET analysis. *Neuropsychologia*, 41, 1868-1876.

Iacoboni, M., Woods, R.P., Brass, M., Bekkering, H., Mazziotta, J.C., & Rizzolatti, G. (1999). Cortical mechanisms of human imitation. *Science*, 286, 2526-2528.

Imada, T., Zhang, Y., Cheour, M., Taulu, S., Ahonen, A., & Kuhl, P.K. (2006). Infant speech perception activates Broca's area: a developmental magnetoencephalography study. *NeuroReport*, 17, 957-962.

Knaus, T.A., Bollich, A.M., Corey, D.M., Lemen, L.C., & Foundas, A.L. (2006). Variability in perisylvian brain anatomy in healthy adults. *Brain and Language*, 97, 219-232.

Kononova, E.P. (1949). The frontal lobe (in Russian). In: Sarkisov, S.A., Filimonoff, I.N., & Preobrazhenskaya, N.S. (editors). *The Cytoarchitecture of the Human Cortex Cerebri*. Moscow: Medgiz, pp. 309-343.

Krams, M., Rushworth, M.F., Deiber, M.P., Frackowiak, R.S., & Passingham, R.E. (1998). The preparation, execution and suppression of copied movements in the human brain. *Experimental Brain Research*, 120, 386-398.

- Kreht, H. (1936). Cytoarchitektonik und motorisches Sprachzentrum. *Zeitschrift für mikroskopisch-anatomische Forschung*, 39, 331-354.
- Maess, B., Koelsch, S., Gunter, T.C., & Friederici, A.D. (2001). Musical syntax is processed in Broca's area: an MEG study. *Nature Neuroscience*, 4, 540-545.
- Nishitani, N., Schürmann, M., Amunts, K., & Hari R. (2005). Broca's region: From action to language. *Physiology*, 20, 60-69.
- Ojemann, G.A. (1991). Cortical organization of language. *Journal of Neuroscience*, 11, 2281-2287.
- Ojemann, G.A. (2003). The neurobiology of language and verbal memory: Observations from awake neurosurgery. *International Journal of Psychophysiology*, 48, 141-146.
- Paulesu, E., Frith, C.D., & Frackowiak, R.S.J. (1993). The neural correlates of the verbal component of working memory. *Nature*, 362, 342-345.
- Paulesu, E., Goldacre, B., Scifo, P., Cappa, S.F., Gilardi, M.C., Castiglioni, I., et al. (1997). Functional heterogeneity of left inferior frontal cortex as revealed by fMRI. *Neuroreport*, 8, 2011-2017.
- Pulvermüller, F. (2005). Brain mechanisms linking language and action. *Nature Reviews Neuroscience*, 6, 576-582.
- Riegele, L. (1931). Die Cytoarchitektonik der Felder der Broca'schen Region. *Journal für Psychologie und Neurologie*, 42, 496-515.
- Rizzolatti, G., & Arbib, M.A. (1998). Language within our grasp. *Trends in Neuroscience*, 21, 188-194.
- Rizzolatti, G., & Craighero, L. (2004). The mirror-neuron system. *Annual Reviews in Neuroscience*, 27, 169-192.
- Scheibel, A.B., Paul, L.A., Fried, I., Forsythe, A.B., Tomiyasu, U., Wechsler, A., Kao, A., & Slotnick, J. (1985) Dendritic organization of the anterior speech area. *Experimental Neurology*, 87, 109-117.

- Sherwood, C.C., Broadfield, D.C., Holloway, R.L., Gannon, P.J., & Hof, P.R. (2003). Variability of Broca's area homologue in African great apes: Implications for language evolution. *The Anatomical Record Part A*, 271A, 276-285.
- Simonds, R.J., & Scheibel, A.B. (1989). The postnatal development of the motor speech area: a preliminary study. *Brain and Language*, 37, 42-58.
- Tomaiuolo, F., MacDonald, J.D., Caramanos, Z., Posner, G., Chiavaras, M., Evans, A.C., & Petrides, M. (1999). Morphology, morphometry and probability mapping of the pars opercularis in the inferior frontal gyrus: an in vivo MRI analysis. *European Journal of Neuroscience*, 11, 3033-3046.
- Uylings, H.B.M., Malofeeva, L.I., Bogolepova, I.N., Jacobsen, A.M., Amunts, K., & Zilles, K. (2005). No postnatal doubling of number of neurons in human Broca's areas (Brodmann areas 44 and 45)? A stereological study. *Neuroscience*, 136, 715-728.
- von Economo, C., & Koskinas, G.N. (1925). *Die Cytoarchitektonik der Hirnrinde des erwachsenen Menschen*. Wien & Berlin: Verlag von Julius Springer, 810pp.
- Watkins, K., & Paus, T. (2004). Modulation of motor excitability during speech perception: the role of Broca's area. *Journal of Cognitive Neuroscience*, 16, 978-987.
- Wilson, S.M., Saygin, A.P., Sereno, M.I., & Iacoboni, M. (2004). Listening to speech activates motor areas involved in speech production. *Nature Neuroscience*, 7, 701-702.
- Zatorre, R.J., Meyer, E., Gjedde, A., & Evans, A.C. (1996). PET studies of phonetic processing of speech: Review, replication, and reanalysis. *Cerebral Cortex*, 6, 21-30.

FIGURE CAPTIONS

Figure 1. The position of Broca's area (opercular and triangular part of the inferior frontal gyrus) in cytoarchitectonic maps of the adult human cerebral cortex. A) In the map of Brodmann (1909), opercular part is occupied by area 44, and triangular part by area 45. B) In the map of von Economo and Koskinas (1925), area FCBm is situated in opercular, and area FDgamma in triangular part of the inferior frontal gyrus. C,D) Note that in Brodmann's (1909, 1912) architectonic classification (C) the inferior frontal gyrus represents a separate cortical region (regio frontalis inferior) consisting of areas 44, 45, and 47. On the other hand, in the classification of von Economo and Koskinas (D) opercular area FCBm is part of praerolandic region while triangular area FDgamma is part of the frontal region.

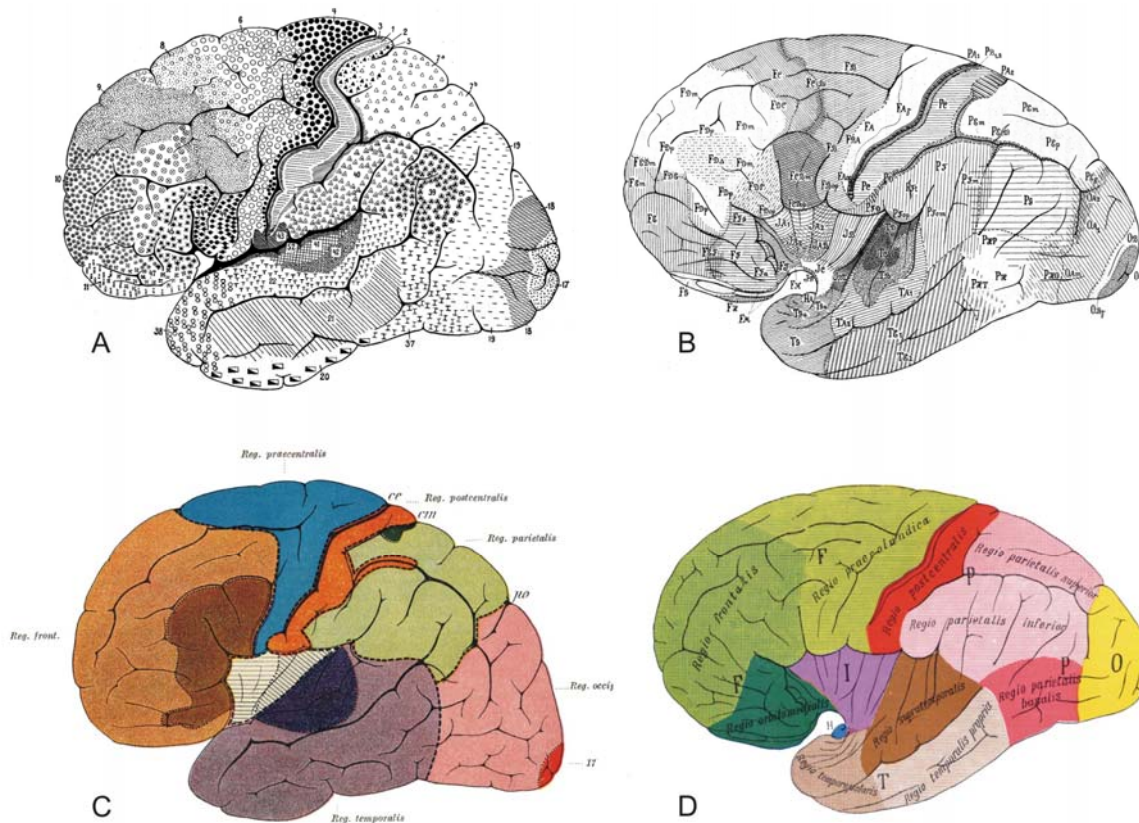


Figure 2. The cortex of Broca's area is typical six-layered isocortex. A) The classic diagram of Brodmann (1909) displays six cortical layers in both cytoarchitectonic (left) and myeloarchitectonic (right) histological sections. Note that layers II and IV are granular (i.e., composed of small, granular cells) while layers III and V consist of small, medium and large pyramidal neurons. As layer IV is usually positioned at the middle of cortex, layers II and III are described as supragranular (lamina superficialis) and layers V and VI are described as infragranular (lamina profunda). B) The classic diagram of von Economo and Koskinas (1925) displays gradual transformation of frontal cortex cytoarchitecture from agranular motor-premotor region (FA, FB) to typical granular prefrontal associative cortex (FE, FG). Note that cortex of Broca's area represents a special portion of intermediate/transitional cortical zone (FC, FD) which is characterized by visible but poorly developed cortical layer IV. Therefore, the cortex of Broca's region is described as dysgranular, in contrast to agranular (no layer IV) motor-premotor cortex and granular (fully developed layer IV) prefrontal cortex.

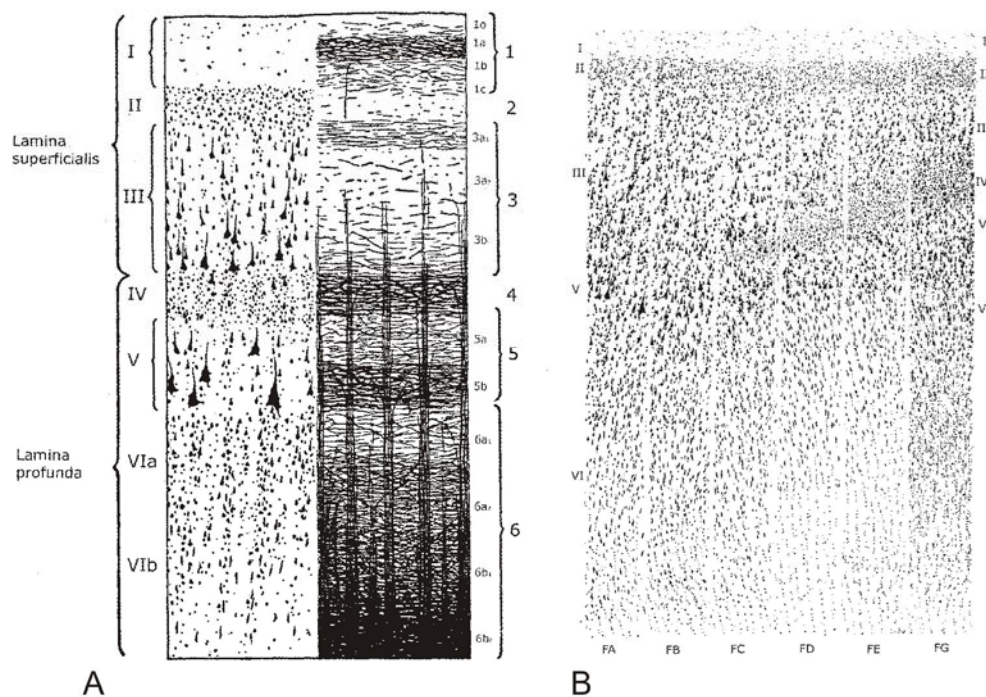


Figure 3. Two major defining features of Broca's area are magnopyramidity and dysgranularity. In classical diagrams of von Economo and Koskinas (1925), note that Broca's area contains very large pyramidal neurons (black triangles) in layer III (magnopyramidity) and layer V (A), and has visible but poorly developed (dysgranular) layer IV (B, the density of dots corresponds to the level of development of layer IV). C) Note that, according to classification of von Economo and Koskinas, opercular area 44/FCBm and triangular area 45/FDgamma belong to different types of cortex - transitional pyramidal type 1(2) for area 44 vs. granular pyramidal type 2 for area 45.

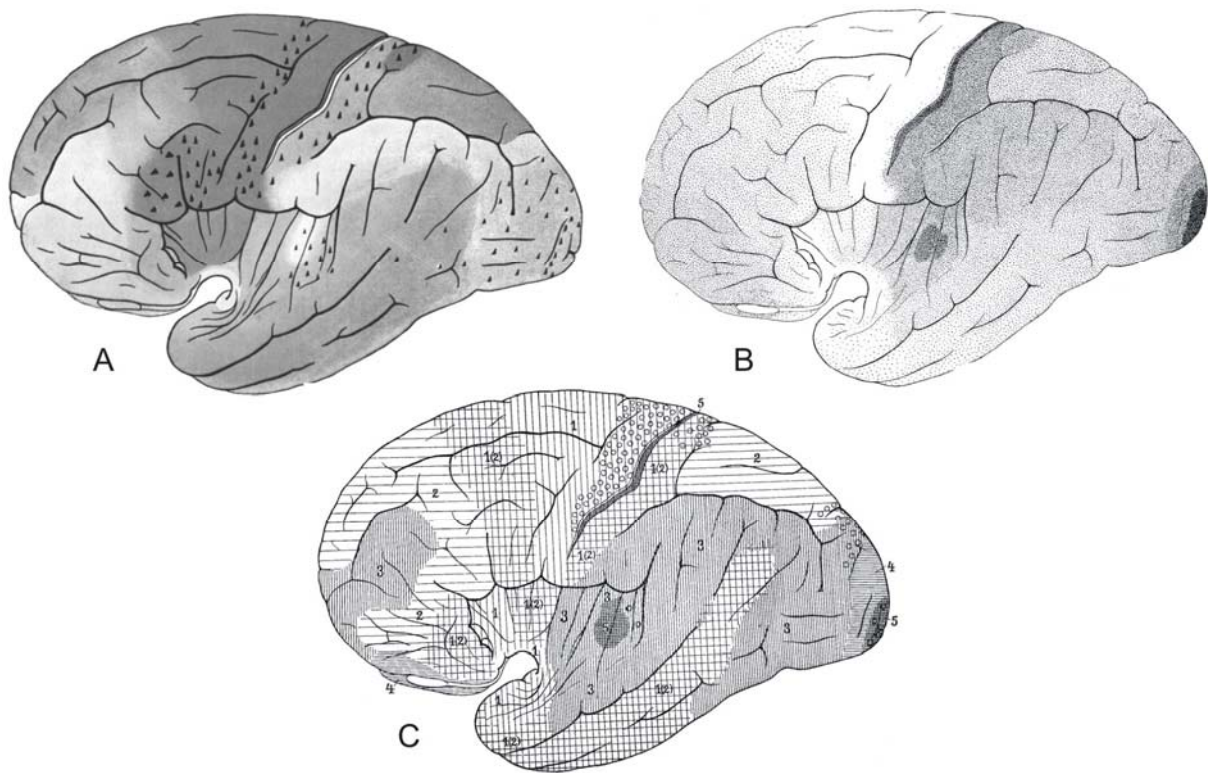


Figure 4. Immature cortex of Broca's area in prematurely born human infants. Nissl stained coronal sections through the fronto-opercular region of 35. postovulatory weeks (A) and 32. postovulatory weeks old premature newborns. Note that layer IV is thick and prominent (low magnification insets from areas depicted by rectangles; bar = 100 um) and that very immature pyramidal neurons of layer III have a barely visible cytoplasm (arrows in high magnification microphotographs; bar = 50 um).

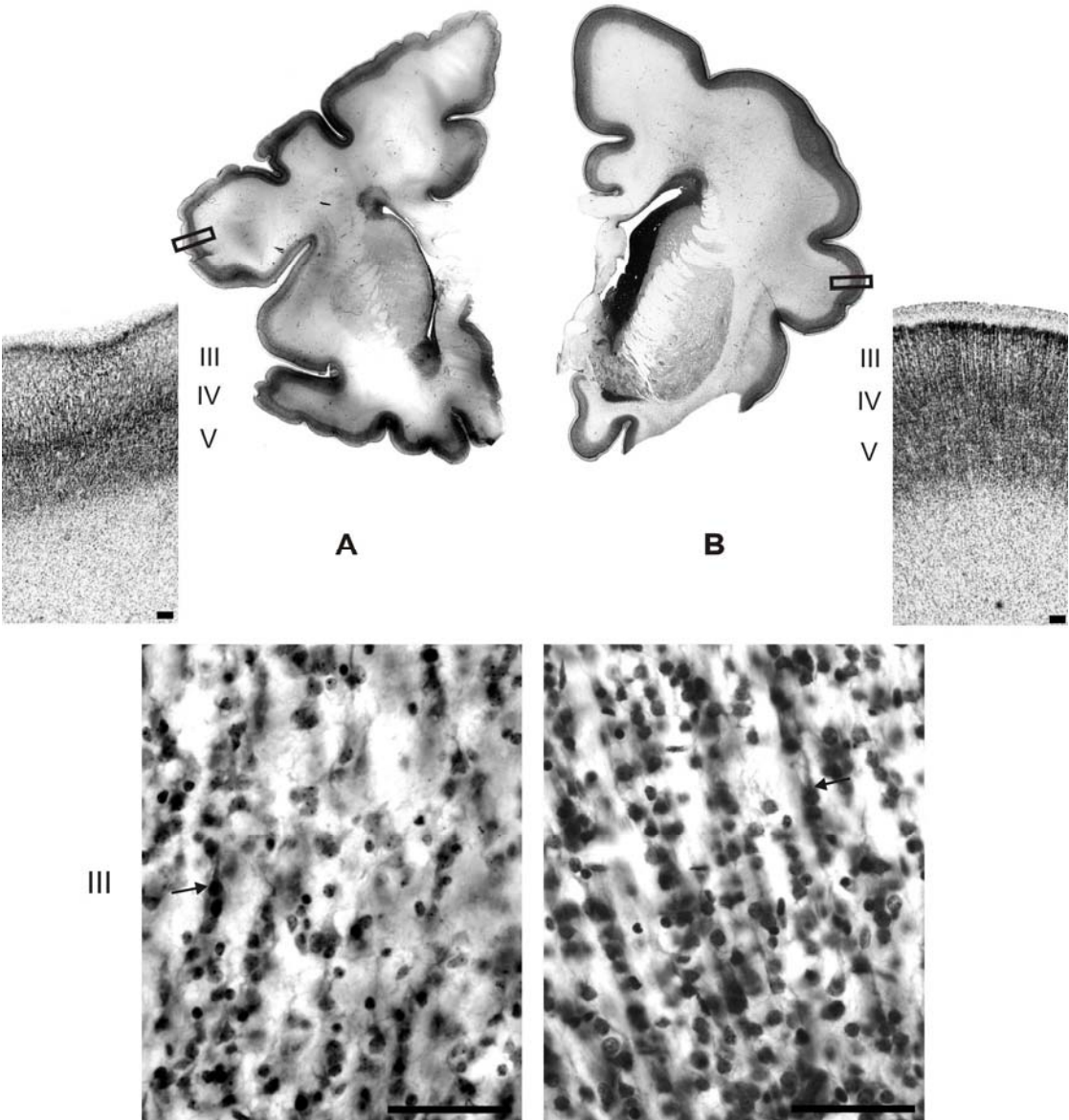


Figure 5. Nissl stained sections through opercular area of 3-month-old infant. Note that layer IV is still dense and prominent (low magnification, left) and that layer III and layer V pyramidal neurons are much better differentiated than in newborn but remain of approximately equal size (high magnification, right). Bar in all photographs = 50 μ m.

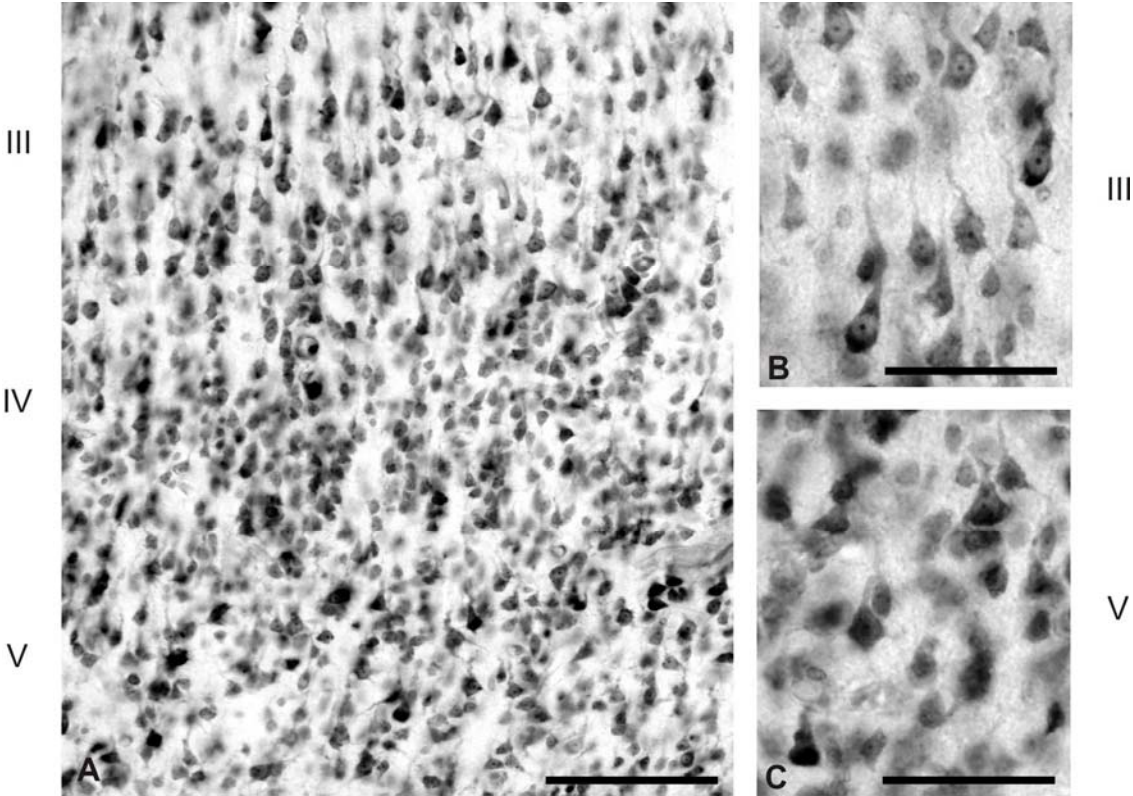


Figure 6. Nissl stained section through opercular area of 18-month-old child. Note that layer IV has significantly decreased cell-packing density (A) and contains scattered large pyramidal neurons (C). Note also that at least some pyramidal neurons of layer III (B) seem to be larger than pyramidal neurons of layer V (D). Bars = 50 μ m.




Figure 7. Nissl stained section through triangular area of 3-year-old child. Note that layer IV (A) is dysgranular, but better developed than in opercular region (compare with figure 6A). On the other hand, the majority of layer III pyramidal neurons (B) still are not larger than pyramidal neurons of layer V (C). Bar in A = 100 μ m; bars in B,C = 50 μ m.

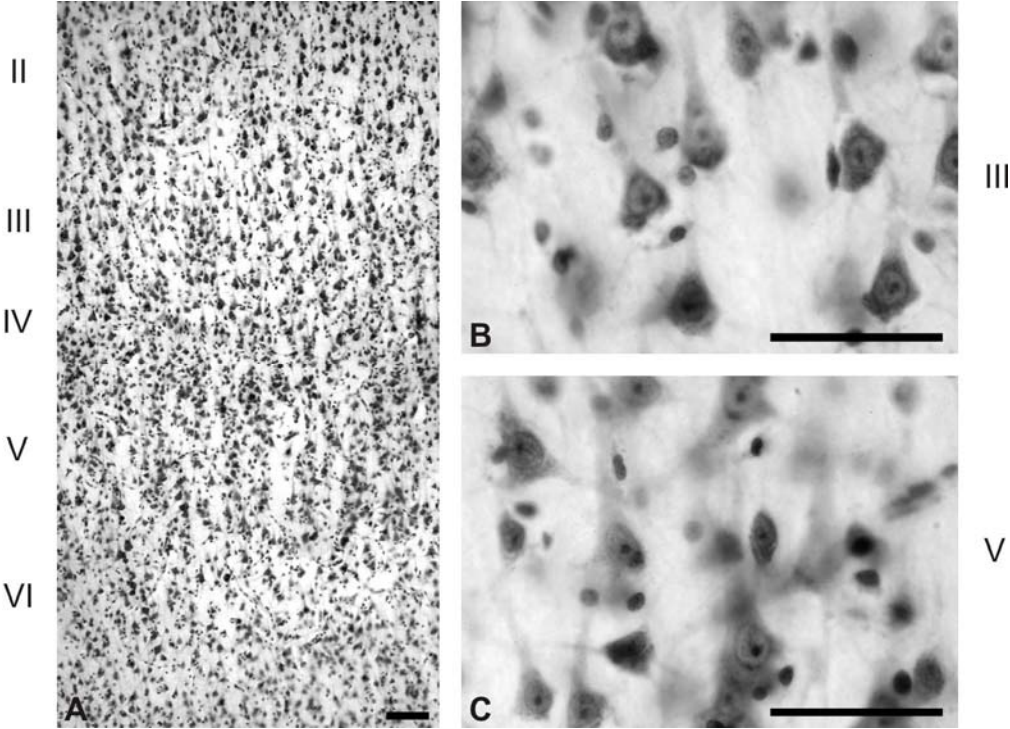


Figure 8. Silver-stained coronal section through opercular area of 7-year-old child. Note that layer IV is clearly dysgranular (A), and that layer III pyramidal neurons (B) are clearly larger (arrows in B) than pyramidal neurons of layer V (C). Bar in A = 100 μ m; bars in B,C = 50 μ m.

