

Comparative Analysis of Hepatocellular Carcinoma in Men and Dogs

Željko Grabarević¹, Marijana Ćorić², Sven Seiwert³, Petar Džaja⁴, Branka Artuković¹,
Andrea Gudan Kurilj¹, Ana Beck¹, Marko Hohšteter¹, Ivan-Conrado Šoštarić-Zuckermann¹,
Luka Brčić³ and Irena Hrستیć⁵

¹ Department of General Pathology and Pathological Morphology, Veterinary Faculty Zagreb, University of Zagreb, Zagreb, Croatia

² Clinical Department of Pathology and Cytology, University Hospital Center «Zagreb», Zagreb, Croatia

³ Institute of Pathology, School of Medicine, University of Zagreb, Zagreb, Croatia

⁴ Department of Forensic Veterinary Medicine, Veterinary Faculty Zagreb, University of Zagreb, Zagreb, Croatia

⁵ Clinical Department of Internal Medicine, University Hospital Center «Zagreb», Zagreb, Croatia

ABSTRACT

Concerning the important differences in the etiopathology of hepatocellular carcinomas (HCC) in humans and dogs, our work describes the expression of epidermal growth factor receptor (EGFr), cytokeratine 19 (CK19), vascular endothelial growth factor (VEGF) and transforming growth factor beta receptor (TGFβ-r) in tumors arising in both species. Investigation included 25 cases of human and 8 cases of dog tumors. All human cases were noted in cirrhotic livers, while in dogs the tissue adjacent to tumor was not changed. In humans in two cases hepatitis B virus (HBV) and in one case hepatitis C virus (HCV) were determined. Investigation showed lack of TGFβ-r reaction in six cases of canine HCC, while in humans only one case was negative. In most tumors specific hepatocyte antigen Hepatocyte Paraffin 1 marker (Hep Par 1) was mainly positive with markedly decreased reaction compared to the normal hepatocytes, while cytokeratine 19 for biliary epithelium was negative. The result of our investigation rise the question about the possible role of tumor suppressor gene TGFβ-r in the development of HCC in dogs and in the same time emphasizes its importance in human diseases.

Key words: hepatocellular carcinoma, men, dogs, histology, EGFr, CK19, p53, VEGF, TGFβ-r, Hep Par 1

Introduction

Hepatocellular carcinoma (HCC) constitutes approximately 5.4% of cancers in humans, but in some parts of the world (Asia and Africa) this tumor is much more common^{1,2}. In animals HCC occurs in numerous species but it seems that they are more common in dogs and cats than ruminants, pigs and horses. However, compared to humans these tumors are much less common and the incidence in dogs has been reported to be less than 1% of all neoplasms³. Concerning the pathogenesis it is well known that cirrhosis and viral infections (HBV/hepatitis B virus/ and HCV/hepatitis C virus) has major influence on HCC occurrence in humans¹. In dogs the situation is quite opposite. Namely, »hepatobiliary tumors in domestic animals are not obvious successors to antecedent liver disease«⁴. It also should be noted that the prevalence of spontaneous HCC is very different between

humans, rats, mice and dogs and that the prevalence of HCC is higher in mice and rats than in humans⁵. Despite obvious very different pathogenesis of the HCC in dogs and humans, histopathological types of tumors are very similar. Namely, in both species there are trabecular, pseudoglandular or adenoid and solid or poorly differentiated forms of tumors. In humans there is one more type or fibrolamellar carcinoma^{1,3}.

Concerning the liver mitogens, it is well known that epidermal growth factor (EGF) and transforming growth factor alpha (TGFα) are important hepatocytic mitogens⁶, vascular endothelial growth factor (VEGF) is very important for tumor angiogenesis⁷, while p53 and transforming growth factor beta (TGFβ) with its receptors (TGFβ-r) are tumor suppressor genes^{8,9}.

The present study evaluated cellular reactivity and localization of epidermal growth factor receptor (EGFr), p53, VEGF and TGFβ-r in human and dog HCC. Tumor diagnosis was established using histopathological evaluation, and immunohistochemical reactivity to cytokeratin 19 (CK19) (for cholangiocellular carcinomas) and hepatocyte antigen Hep Par1 (for HCC)10. The results of the study could be helpful in determining existing species differences in tumor development.

Materials and Methods

Selection of human and canine patients

Liver specimens with HCC were obtained from 25 humans and 8 dogs. Human cases were biopsies (with HBV and HCV status) while animal cases were obtained on necropsy during the years 2005–2008. Histopathological analysis was performed using hematoxylin and eosin (HE) staining.

Immunohistochemistry study

Liver specimens were fixed in 10% neutral-buffered formalin and subsequently embedded in paraffin. Serial 4mm thick sections were acquired from each paraffin block. Paraffin sections of all specimens were deparaffinised in xylene and then rehydrated through graded alcohol. Endogenous peroxidase activity was blocked with 0.3% hydrogen peroxide for 10 min. The following antibodies were used for immunohistochemistry: anti-human hepatocyte, anti – human Cytokeratin 19, anti – human Epidermal Growth Factor Receptor, anti – human Vascular Endothelial Growth Factor monoclonal mouse antibodies (Dako Glostrup, Denmark) and mouse monoclonal Transforming Growth Factor Beta Receptor antibody (Novocastra). Immunostaining was performed by the avidin biotin peroxidase complex (ABC) method using LSAB+, Dako, Glostrup, Denmark kit. The immunostaining results were interpreted using a light microscope with 40x objective. In each specimen we analysed 3 microscope fields in the most positive area of the tumor (hot spot). Positivity was assessed by a semiquantitative method on a scale from 0 to 3.

Results

Histopathology

In humans liver cirrhosis was seen in all cases of HCC. In three patients viral hepatitis was determined i.e. two cases of HBV and one case of HCV infection. Histopathological tumor patterns were of mixed type, namely in the same tumor various types were seen, predominately trabecular and pseudoglandular types. HCC in dogs was in 6 cases trabecular type, in two solid type, and no signs of some other liver diseases were noted. The diagnosis of HCC was additionally established with Hep Par 1 and CK19 immunohistochemical reaction of the tumor tissue.

TABLE 1
IMMUNOHISTOCHEMICAL STAINING IN PARAFFIN EMBEDDED HUMAN HEPATOCELLULAR CARCINOMAS WITH ANTIBODIES TO EGF-r, CK19, VEGF AND TGFβ-r

Case number	EGF-r score	CK19 score	VEGF score	TGFβ-r score
1.	0	0	0	2
2.	2	0	3	3
3.	2	0	3	3
4.	1	0	1	2
5.	0	3	0	0
6.	3	0	2	3
7.	3	0	3	3
8.	3	0	3	3
9.	2	0	3	3
10.	1	0	3	3
11.	0	0	2	3
12.	0	0	3	3
13.	3	1	3	3
14.	3	1	3	3
15.	1	2	1	2
16.		0	3	3
17.		0	3	3
18.	3	0	3	3
19.	3	3	3	3
20.	0	3	0	1
21.	3	0	3	3
22.	3	0	3	3
23.	3	2	3	2
24.	3	1	1	3
25.	3	3	3	3

Score – 0-3, EGF-3 – epidermal growth factor receptor, CK19 – cytokeratin 19, VEGF – vascular endothelial growth factor, TGFβ-r – transforming growth factor beta receptor

Immunohistochemistry study

The results of immunohistochemical staining are shown in Tables 1 and 2 for human and dog tumors respectively. EGFr was positive in 18 and negative in 5 human cases. Reaction score was in most instances 3, and the reaction was visible as cytoplasmic granular material. The same pattern was seen in dogs in which in five cases there was positive staining while three were negative. The expression of VEGF was even more pronounced, namely only three human tumors were negative and 22 were positive with predominately largest score. In dogs, reaction was less apparent compared to humans but positive reaction was present in five tumors. Also the reaction score was less intense. Staining was cytoplasmic and finely granular. Most apparent differences were noted in TGFβ-r staining. Namely, in human HCC predominately highly positive reaction was seen in almost all tumors (24) and only in one case there were no expression.

TABLE 2
IMMUNOHISTOCHEMICAL STAINING IN PARAFFIN EMBEDDED DOG HEPATOCELLULAR CARCINOMAS WITH ANTIBODIES TO EGF-r, CK19, VEGF AND TGFβ-r.

Case number	EGF-r score	CK19 score	VEGF score	TGFβ-r score
1.	0	0	0	0
2.	3	0	3	0
3.	1	0	1	0
4.	3	0	3	2
5.	0	0	0	0
6.	2	0	1	0
7.	0	0	0	0
8.	3	0	3	3

Score – 0-3, EGF-3 – epidermal rowth factor receptor, CK19 – cytokeratine 19, VEGF – vascular endotrhelial growth factor, TGFβ-r – transforming growth factor beta receptor

The intensity score was predominately high not only in tumor but also in adjacent cirrhotic liver tissue (Figure 1). The staining was finely granular and cytoplasmic. On the contrary, in dogs in six tumors there was no reaction at all, and positive tumor cells were noted only in two cases. It is also interesting that normal hepatocytes in the tissue adjacent to tumor show a positive reaction (Figure 2). Reaction was cytoplasmic but coarsely granular. CK 19 immunostaining was negative in all cases, while Hep Par 1 was markedly less apparent in tumor comparing to the normal liver tissue (Figure 3) and in two cases of solid type the reactions were negative.

Discussion

TGFβ and its receptors have been implicated as tumor suppressor genes and important antimitogenic fac-

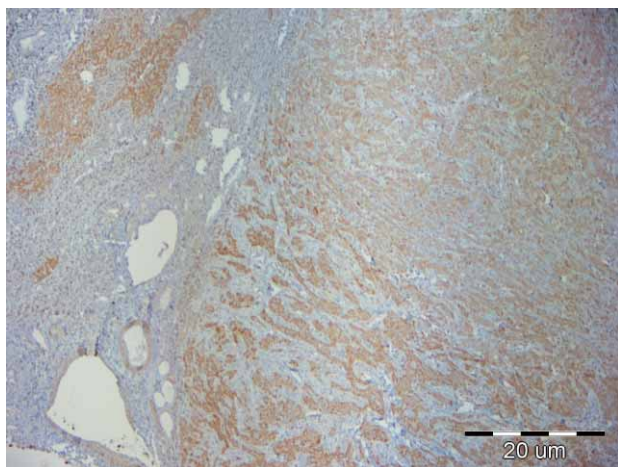


Fig. 1. Liver, human. HCC and cirrhosis. TGFβ-r expression in tumor cells as well as in hepatocytes. Hematoxylin counterstain. Bar 20 μm.

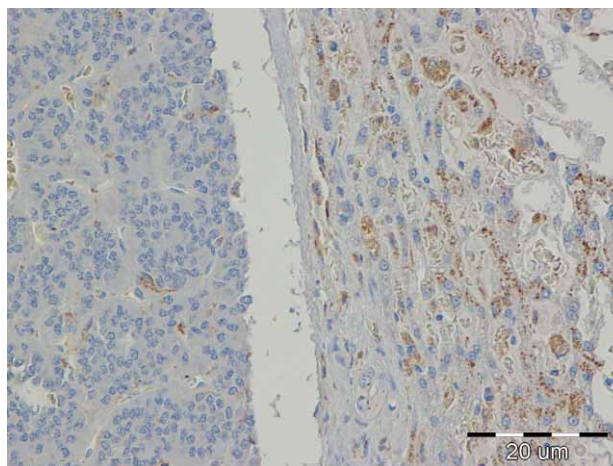


Fig. 2. Liver, dog. HCC. Granular staining with TGFβ-r of the compressed hepatocytes on the right and lack of reaction of the tumor tissue on the left side of the figure. Hematoxylin counterstain. Bar 20 μm.

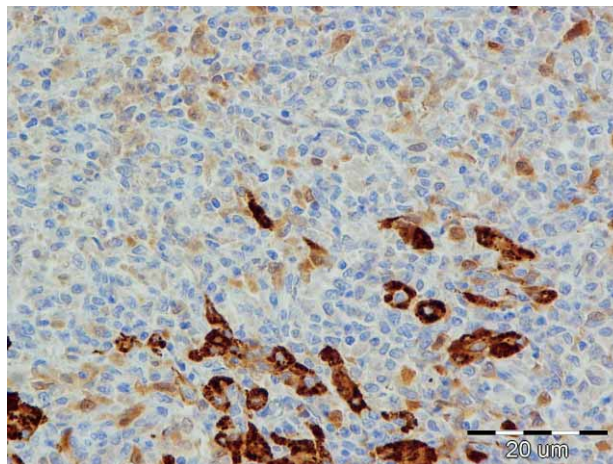


Fig 3. Liver; dog. HCC. Some tumor cells and individual hepatocytes react with Hep Par 1. Hematoxylin counterstain. Bar 20 μm.

tors in the liver and gastrointestinal tract. It was shown that inactivation of its signaling in hepatocytes results in an increased proliferative response after partial hepatectomy in knockout mice⁸. Also, it is well known that its inactivation leads to development of the pancreatic carcinomas and colonic cancers¹¹. Generally, TGFβ is a growth inhibitor for most epithelial cell types and for leukocytes¹² and because of that loss of its receptors frequently occurs in various tumors as it was earlier mentioned. However, in the literature we were not able to find this concerning the HCC in dogs. It may be supposed that loss of TGFβ-r plays a crucial role in carcinogenesis of this tumor especially because of the facts that adjacent hepatocytes have normal reactivity and that this tumor develops in apparently normal liver tissue. This finding also has important impact on HCC in humans and probably provides new insight in its development. The role of

VEGF and EGF receptor in tumor growth and progression is well known and their expression is widely used in the estimating degree of malignancy in various tumors^{6,13,14}. In this work their expression was very similar to these literature data.

REFERENCES

1. CRAWFORD JM, Liver and Biliary Tract. In: KUMAR V, ABBAS AK, FAUSTO N (Eds) Robbins and Cotran Pathologic Basis of Disease (Elsevier Saunders, Philadelphia, 2005). — 2. MONTO A, WRIGHT TL, Semin Oncol, 28 (2001) 441. — 3. CULLEN JM, POPP JA, Tumors of the Liver and Gall Bladder. In: MEUTEN DJ (Ed) Tumors in Domestic Animals (Iowa State Press, Ames, 2002). — 4. STALKER MJ, HAYES MA, Liver and Biliary System. In: MAXIE MG (Ed) Jubb, Kennedy, and Palmers Pathology of Domestic Animals (Saunders Elsevier, Edinburgh London New York Oxford Philadelphia St Louis Sydney Toronto, 2007). — 5. KOBAYASHI K, HAGIWARA T, MIURA D, OHORI K, TAKEUCHI H, KANAMORI M, TAKASAKI K, J Environ Biol, 20 (1999) 189. — 6. BORLAK J, MEIER T, HALTER R, SPANEL R, SPANEL-BOROWSKI K, Oncogene, 24 (2005) 1809. — 7. BLOOME EAG, DEL PIERO F, KOLAJA KL, Tumorska angiogeneza. In: GRABAREVIĆ Ž (Ed) Veterinarska

Acknowledgements

The work was supported by Ministry of Science, Education and Sport grants no. 053-0532264-2260, 053-0532264-3129 and 108-0532264-0048.

onkologija (DSK-FALCO, Zagreb, 2002). — 8. ROMERO-GALLO J, SOZMEN EG, CHYTIL A, RUSSELL WE, WHITEHEAD R, PARKS WT, HOLDREN MS, HER MF, GAUTAM S, MAGNUSON M, MOSES HL, GRADY WM, Oncogene, 24 (2005) 3028. — 9. YOON YJ, CHANG HY, AHN SH, KIM JK, PARK YK, KANG DR, PARK JY, MYOUNG SM, KIM DY, CHON CY, HAN KH, Carcinogenesis, 29 (2008) 1192. — 10. RAMOS-VARA JA, MILLER MA, JOHNSON GC, Vet Pathol, 38 (2001) 636. — 11. MIYAKI M, KUROKI T, Biochem Biophys Res Commun, 306 (2003) 799. — 12. MOUSTAKAS A, PARDALI K, GAAL A, HELDIN CH, Immunol Lett, 82 (2002) 85. — 13. MOON WS, PARK HS, YU KH, PARK MY, KIM KR, JANG KY, KIM JS, CHO BH, Human Pathol, 37 (2006) 1324. — 14. YANG EB, WANG DF, CHENG LY, MACK P, Cancer J, 10 (1997) 319.

Ž. Grabarević

Veterinary Faculty, University of Zagreb, Heinzelova 55, 10000 Zagreb, Croatia
e-mail: zgrabar@vef.hr

KOMPARATIVNA ANALIZA HEPATOCELULARNIH KARCINOMA LJUDI I PASA

SAŽETAK

S obzirom na značajne razlike etiopatologije hepatocelularnih karcinoma (HCC) ljudi i pasa, naš rad opisuje ekspresiju receptora epidermalnog faktora rasta (EGFr), citokeratina 19 (CK19), faktora rasta podrijetla vaskularnog endotela (VEGF) i receptora za transformirajući factor rasta beta (TGFβ-r) u obje vrste. Istraživanje je onuhvatilo 25 slučajeva HCC u ljudi i 8 slučajeva HCC u pasa. U ljudi se ovaj tumor u svim slučajevima pojavio u jetri zahvaćenoj cirotičnim promjenama, dok je u pasa dio jetre nezahvaćen tumorom bio nepromijenjen. U ljudi je u dva slučaja utvrđena infekcija s virusom hepatitisa B, a u jednom s virusom hepatitisa C. Istraživanje je pokazalo izostanak reakcija na TGFβ-r u šest tumora pasa, dok je ova reakcija izostala samo u jednom tumoru ljudi. Hepatocitni antigen Hep Par 1 je u većini tumora bio pozitivan sa značajno smanjenim intenzitetom reakcije u usporedbi s normalnim hepatocitima, dok je CK19 specifičan za bilijarni epitel bio negativan. Rezultati istraživanja ukazuju na značenje TGFβ-r u nastanku HCC u pasa i istodobno naglašavaju njegovo značenje u ovom tumoru ljudi.