

Giant Basal Cell Carcinoma of the Back: A Case Report and Review of the Literature

Branko Bogdanić¹, Sanda Smud¹, Dinko Bagatin¹, Marin Nola², Davor Mijatović¹ and Matea Majerović³

¹ Department of Surgery, University Hospital Center »Zagreb«, Zagreb, Croatia

² Department of Pathology, University Hospital Center »Zagreb«, Zagreb, Croatia

³ School of Medicine, University of Zagreb, Zagreb, Croatia

ABSTRACT

Basal cell carcinoma (BCC) is the most common cutaneous malignancy and the most common human malignancy in general. Out of all basal cell carcinomas, giant basal cell carcinoma represents less than 1%. Only 10% of all basal cell carcinomas are located on the trunk and majority is located on the head and neck. We describe a patient with a exophytic giant basal cell carcinoma of the back size 8.5 × 8 × 6 cm, infiltrating skin 1.5 cm. Two years after the lesion has occurred, diagnosis was made by pathohistological analysis. The patient was treated surgically, by excision. Review of the literature that refers to giant basal cell carcinoma was carried out.

Key words: giant basal cell carcinoma, basal cell carcinoma

Introduction

Basal cell carcinoma (BCC) is the most common cutaneous malignancy and the most common human malignancy in general. Statistical data for BCC is unknown, because in spite of all other types of carcinomas, BCC is not reported to cancer registries. According to American Cancer Society in the United States, in 2007 there were 800 000–900 000 cases of BCC. Incidence of BCC in United States is 500–1000 per 100 000. Incidence of BCC increases at a rate of 3 % per year. In 80–85 % of cases BCC is most often located on the head and neck, while only 10 % occurs on the trunk^{1,2,3}.

Giant basal cell carcinoma (GBCC) is defined as a tumor larger than 5 cm in diameter and represents less than 1 % of all basal cell carcinomas. Majority of GBCCs are located on the trunk. The size of the tumor depends on numerous factors and the leading one is neglect. GBCC tend to extend into extradermal structures such as muscle, bone and cartilage^{3–7}.

Case Report

A 71-year-old female patient presented with a large cutaneous tumor on her back. The patient waited two years before coming to our clinic. The lesion was mostly

asymptomatic. From time to time she felt itching and little discomfort. She was certain that the lesion was very small, size 0.5 cm.

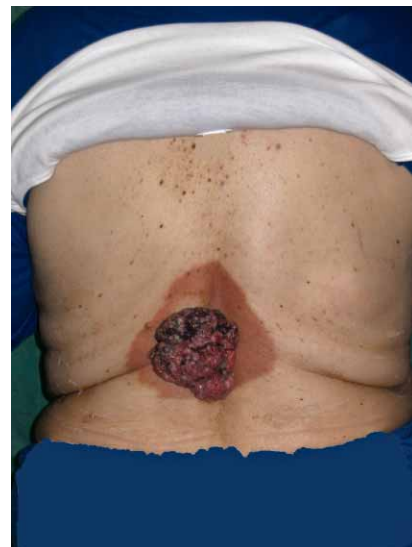

Fig. 1. Exophytic tumor size 8,5 × 8 × 6 cm.

Her family history was noncontributory. She had appendectomy, gall-stones, osteoarthritis of hip and knee and mild hypertension.

Physical examination revealed well-margined, painless, exophytic tumor size 8.5 × 8 × 6 cm which easily dripped serum and blood. Surface of the tumor was partially ulcerated, with small necrotic areas. Skin around the tumor was erythematous. (Figure 1.) There was no evidence of lymph node involvement.

Chest radiography, ultrasound of the liver, scintigraphy with technetium Tc 99m MDP and laboratory test were made preoperatively and were all negative. However, MSCT scan revealed an expansive tumor measuring 8 × 6 cm on the back, paramedial left, on the skin in level with 10th thoracic vertebra. Tumor was well vascularized, without signs of necrosis (Figure 2).

Excision of the tumor with the surrounding skin measuring 15.5 × 15 × 2 cm was made. Excision margins were 1 cm from the macroscopic border of the erythematous skin (Figure 3).

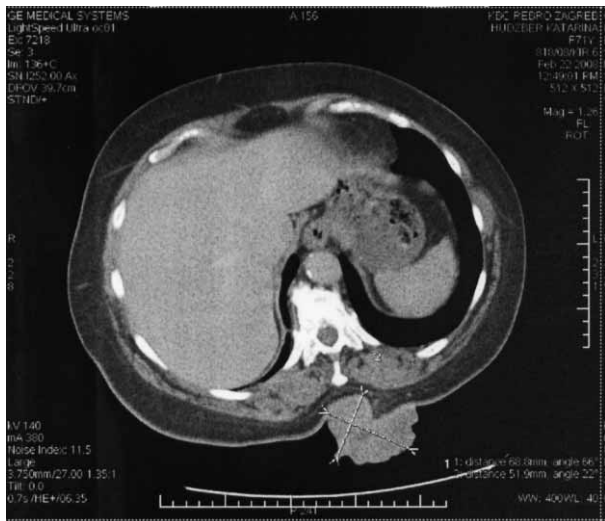

Fig. 2. MSCT scan revealed an expansive tumor size 7 × 5 cm on the back, in level with 10th thoracic vertebra.

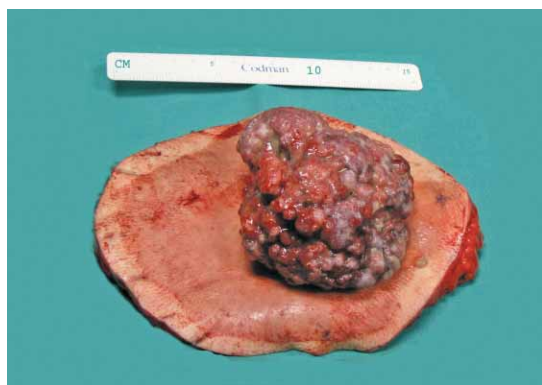

Fig. 3. Excision of the skin with the tumor on top, size 15,5 × 15 × 2 cm.

Pathohistological findings revealed regular epidermis on the surface of the excised erythematous skin that was surrounding the tumor. Tumor consists of nests of atypical epithelial basaloid cells with peripherally palisading cells. Stroma surrounds nests of tumor cells and in some nests keratinization is presented. Infiltration of skin was 1.5 cm and the surgical margins were negative. Tumor was completely removed (Figure 4).

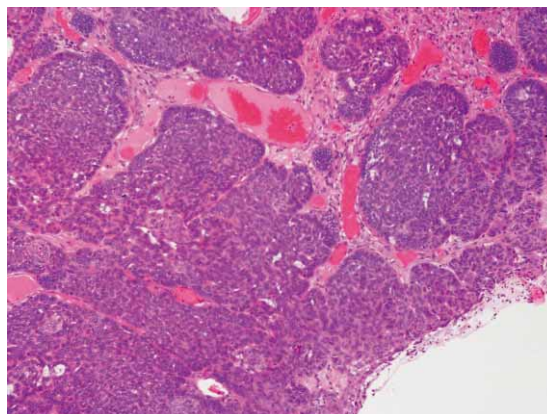


Fig. 4. Pathohistological findings of surgically removed tumor, hemalaun-eosin staining.

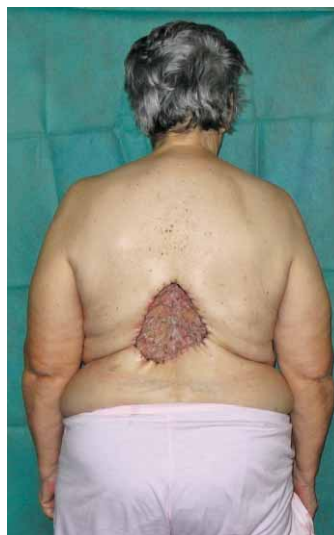

Fig. 5. On the defect of the skin Thiersch' graft was transplanted.

Excised skin defect was covered with split thickens skin graft from the right upper thigh (Figure 5). Three months after the surgery, wound is healing properly.

Discussion

The etiology of BCC is unknown. However, various endogenous and exogenous factors, single or joined may be responsible for the development of BCC. The majority of BCCs are acquired and develop on the chronically sun-exposed skin in adults (head and neck), which indicates that UV radiation is one of the main causes. Ultra-

violet B (UVB) radiation (sunburn spectrum 290–320 nm) is considered to be specially dangerous. UVB radiation damages DNA by causing aberrant covalent bonds, its repair system and immune system. All that results in progressive genetic alternation and forming of neoplasms. Fair-skinned persons (red or blond hair, freckling, skin types I and II) are especially at risk. Other exogenous risk factors include sun bed use, PUVA therapy, chronic systemic exposure to toxic substances such as polycyclic aromatic amines and inorganic arsenic, immunosuppression, radiotherapy, or previous traumas such as burns. Other risk factors are family history of skin cancer, advanced age, male sex, amyloidosis^{3–5,8}.

Basal cell nevus syndrome (Gorlin-Goltz syndrome) is an autosomal dominant disease that is characterized by multiple BCCs, cysts in mandibula and long bones, kyphoscoliosis, calcification of the falx, ovarian fibromas and eye abnormalities. Mutation of the gene is located on chromosome 9q22.3-q31.

Classification for BCC is not generally accepted. The American Joint Committee on Cancer Classification defined BCCs as following: T1 – tumor sized 2 cm or less in the greatest diameter, T2 – tumors bigger than 2 cm, but less than 5 cm, T3 – tumor size 5 cm to more (giant basal cell carcinoma). As distinguished from the American Joint Committee on Cancer Classification, some reports define GBCC as a tumor 10 cm or larger in diameter^{4,7,9}.

GBCC is usually seen in patients over 50 with poor education (received only elementary school degree) and often with other health problems (for example, chronic alcoholism, iron deficiency, depression, impaired immunological function, Alzheimer's disease, amyloidosis, human Papillomavirus infection). Location of GBCC is usually on the less visible area^{4–6}.

One of the main reasons for developing GBCC is neglect. Neglect can be ambiguous: from the patient and/or from the doctor. Patients neglect is a result of denial, poor education (received only elementary school degree), cognitive impairment (Alzheimer's disease) or they were simply »too busy«. Many of the patients saw physicians routinely, but they received inadequate treatment of small BCCs or physician was not thorough in examining them^{4–6}.

In the present case we reported a patient that had several risk factors: old age, poor education (did not receive elementary school degree) and the location of the tumor on the back (less visible area). The patient waited over two years before visiting a doctor. As she reported, she did not want to disturb her family and family doctor. She thought it was nothing dangerous. She treated primary lesion self-initiatively with an antibiotic ointment, which was not efficient. An unexpected perception of a close relative detected the tumor. Patient was never exposed to radiation or any kind of immunosuppression.

Frequently GBCC infiltrates extradermal structures such as muscle, bone and cartilage. Histological characteristics of the tumor are important in developing GBCC. Some histologic subtypes (micronodular, morpheaform or metatypical) have been considered to be more aggressive forms of BCC, hereby the size of GBCC is larger. However, other histologic subtypes can also develop GBCC^{3,4,6,7,9,10,12–14}.

Spates et. all reported that the first report of metastatic BCC was in 1894. Although the occurrence of metastasis by BCC is rare (0,03 %) exceeding tumor size increases the incidence of metastasis. Tumors greater than 3 cm have a 2 % incidence of metastasis; tumors greater than 5 cm have increased that risk up to 25 %; with more than 10 cm, this risk increases to 50 %; and when tumor reaches 25 cm in largest diameter metastasis are almost certain to be found. Mortality rate of metastatic GBCC is about 50 % within 8 months and metastasis is almost certain when tumor size exceeds 100 cm². Our patient had tumor size 68 cm², so the absence of metastasis is not surprising. The most common organs affected with metastasis are lung, bone and skin. Mortality is caused due to deep invasion and destruction of muscle, bone, dura causing infection and destruction of big blood vessels^{4,5,12,14,15}.

Treatment of GBCC is generally surgical by excision. In case there is a contraindication for a surgical intervention (e.g. older age, poor surgical candidate due to ongoing medical condition, recurrent tumors, incomplete excision with residual positive surgical margins) radiotherapy can be used. Radiotherapy is often used as a palliative treatment, especially in patients with recurrent disease, but can also be a definitive treatment. Contraindications to radiotherapy are xeroderma pigmentosum and Gorlin-Goltz syndrome. Patients with metastatic disease are being treated with systemic chemotherapy with some success. Different chemotherapeutic agents are being used, such as fluorouracil in combination with vincristine, bleomycine and prednisone. Recently, cisplatin and paclitaxel are being used^{11,16}.

Conclusion

BCC is the most common malignancy and should be treated surgically. Nonhistologically controlled technique, such as cryosurgery, curettage, or electrodesiccation should not be used, because aggressive histologic subtypes of BCC have a very high recurrence rate. Definitive diagnosis is always made by pathologist. Patients with a giant basal cell carcinoma have some characteristic attributes: old age, poor education, neglect, denial and specific location (less visible area), as our patient. Better health care and education, especially in rural sector, could prevent increase of BCC incidence thereby GBCC. Patients with GBCC should be diagnosed and treated as early as possible, with mandatory close follow-up.

REFERENCES

1. American Cancer Society. Detailed guide: skin cancer: non melanoma: http://www.cancer.org/docroot/CRI/content/CRI_2_4_1X_What_are_the_key_statistics_for_skin_cancer_51.asp?sitearea= Accessed June 29, 2007. — 2. WOLFF K et al. In: Fitzpatrick's Color Atlas & Synopsis of Clinical Dermatology, eds Mc Graw – Hill, N.York, 2005, 282–291. — 3. LORENZINI M, GATTI S, GIANNITRAPANI Br J Plast Surg, 58 (2005) 1007. — 4. RANDLE HW, ROENIGK RK, BRODLAND DG, Cancer, 72 (1993) 250. — 5. LACKEY PL, SARGENT LA, WONG L, BRZEZIENSKI M, KENNEDY JW, Annals of Plastic surgery, 58 (2007) 250. — 6. KOKAVEC R, FEDELES J, Acta Chir Plast, 46 (2004) 67. — 7. SAHL WJ, SNOW SN, LEVINE NS, J Am Acad Dermatol, 30 (1994) 856. — 8. BULJAN M, BULAT V, ŠITUM M, LUGOVIĆ MIHIĆ L, STANIĆ DUKTAJ S, Acta Clin Croat, 47 (2008) 25. — 9. PRPIĆ MASSARI L, KAŠTELAN M, GRUBER F, Coll Antropol, 31 (2007) Suppl. 1: 83. — 10. SJEROBABSKI MASNEC I, VODA K, ŠITUM M, Coll Antropol, 31 (2007) Suppl. 1: 97. — 11. GRUBER F, ZAMOLO G, KAŠTELAN M, PRPIĆ MASSARI L, ČABRLJAN L, PEHARDA V, BATINEC T, Coll Antropol, 31 (2007) Suppl. 1: 101. — 12. BETTI R, INSELVINI E, MENEGHINI L, CROSTI C, J Dermatol, 24 (1997) 317. — 13. NORTHINGTON M, TAMBURIN L, HAMZAS, DIWAN H, SKELTON H, SMITH K, J Cutan Pathol, 31 (2004) 174. — 14. COPCU E, AKTAS A, Int Semin Oncol, 2 (2005) 1. — 15. SPATES ST, MELLETTE JR Jr, FITZPATRICK J, Dermatol Surg, 29 (2003) 650. — 16. BECK HI, ANDERSEN JA, BIRKLER NE, OTTOSEN PD, Acta Derm Venereol, 63 (1983) 564. — 17. STRINIĆ T, BUKOVIĆ D, BILONIĆ I, HIRŠ I, DESPOT A, BOČAN A, Coll Antropol, 27 (2003) Suppl. 1: 55. — 18. YAMAMOTO S, JOHNO M, KAYASHIMA K, MATSUNAGA W, ONO T, J Dermatol, 23 (1996) 329. — 19. FRESINI A, ROSSIELLO L, SEVERINO BU, DEL PRETE M, SATRIANO RA, SKINmed, 6 (2007) 204. — 20. ROSSI R, CAMPOLMI P, GIOMI B, MASSI D, CAPPUGI P, J Eur Acad Dermatol Venereol, 16 (2002) 374. — 21. JACOBS GH, RIPPEY JJ, ALTINI M, Cancer, 49 (1982) 533. — 22. CURRY MC, MONTGOMERY H, WINKELMANN RK, Arch Dermatol, 113 (1977) 316. — 23. SAHL WJ, Int J Dermatol, 34 (1995) 319. — 24. CENTERBURY TDW, WHEELER WE, MADAN E, W V Med J, 86 (1990) 291. — 25. WENDT JR, HOUCK JR, Contemp Surg, 32 (1988) 33. — 26. LEFFELL DJ, HEADINGTON JT, WONG DS, SWANSON NA, Arch Dermatol, 127 (1991) 1663. — 27. GAUGHAN LJ, BERGERON JR, MULLINS JF, Arch Dermatol, 99 (1969) 594. — 28. BIANCHINI R, WOLTER M, J Dermatol Surg Oncol, 13 (1987) 556. — 29. MC ELROY J, KNIGHT TE, CHAN-STROMAN L, Cutis, 58 (1996) 289. — 30. MAINELLA M, MAJEWSKI WT, LATKOVICH P, MICHAELS BM, Ann Plastic Surg, 41 (1998) 444. — 31. BERKING C, KONZ B, PFUTZNER W, HECKMANN M, Hautarzt, 49 (1998) 719. — 32. ASLAN G, KARGI E, GORGU M, ERDOGAN B, Ann Plast Surg, 44 (2000) 574. — 33. KIKUCHI M, YANO K, KUBO T, HOSOKAWA K, YAMAGUCHI Y, ITAMI S, Br J Plast Surg, 55 (2002) 445. — 34. PITEIRO AB, PEREZ-ESPANA L, HERVELLA M, CASADO M, J Dermatol, 30 (2003) 573. — 35. TAKEMOTO S, FUKAMIZU H, YAMANAKA K, NAKAYAMA T, KORA Y, MINETA H, Scand J Plast Reconstr Surg Hand, 37 (2003) 181. — 36. MOHS FE, JONES DL, KORANDA FC, Arch Dermatol, 116 (1980) 777.

B. Bogdanić

Department of Surgery, University Hospital Center »Zagreb«, Kišpatićeva 12, 10 000 Zagreb, Croatia
e-mail: dr.bogdanic@gmail.com

VELIKI BAZOCELULARNI KARCINOM NA LEĐIMA: PRIKAZ SLUČAJA I PREGLED LITERATURE

SAŽETAK

Bazocelularni karcinom je najčešći malignitet kože, a i najčešći malignitet u ljudi uopće. Od svih bazocelularnih karcinoma, veliki bazocelularni karcinom zauzima < 1%. Samo 10% velikih bazocelularnih karcinoma pojavljuje se na trupu, a većina je smještena na glavi i vratu. Prikazana je bolesnica s velikim egzofitičnim bazocelularnim karcinomom na leđima dimenzija 8,5 × 8 × 6 cm, koji je infiltrirao kožu 1,5 cm. Dijagnoza je postavljena patohistološkom analizom dvije godine nakon pojave lezije. Bolesnica je tretirana kirurški. Iznijeti su podaci iz literature, koji se odnose na veliki bazocelularni karcinom.