

# A rare case of Fitz-Hugh–Curtis syndrome caused by *Chlamydia trachomatis* in an HIV-positive male patient

SAGE Open Medical Case Reports  
Volume 7: 1–4  
© The Author(s) 2019  
Article reuse guidelines:  
sagepub.com/journals-permissions  
DOI: 10.1177/2050313X18823592  
journals.sagepub.com/home/sco



Iva Lisičar<sup>1</sup> , Josip Begovac<sup>1,2</sup> and Šime Zekan<sup>1,2</sup>

## Abstract

Fitz-Hugh–Curtis syndrome, a rare complication of pelvic inflammatory disease, is an inflammation of the liver capsule (thus called perihepatitis) and the surrounding peritoneum. It occurs extremely rarely in men and is typically characterized by a sudden onset of severe pain in the right upper abdominal quadrant. Ultrasound examination of the liver does not reveal any morphologic changes, and liver function tests are usually normal. Computerized tomography shows the thickening of the perihepatic fat, but definitive diagnosis is only possible by direct visualization by laparoscopy or laparotomy. We present a 33-year-old HIV-positive man with *Chlamydia trachomatis* proctitis who developed severe right upper abdominal quadrant pain. Abdominal ultrasound did not show any liver pathology, while computerized tomography revealed hepatic capsular thickening. After 21 days of doxycycline therapy, the patient's symptoms subsided. Based on the clinical presentation and liver computerized tomography examination, the diagnosis of proctitis and the resulting Fitz-Hugh–Curtis syndrome was made. Although it is rarely seen in male patients, it should be a part of differential diagnosis in patients who present with right upper abdominal quadrant pain, especially in men who have sex with other men.

## Keywords

Infectious diseases, Fitz-Hugh–Curtis syndrome, men who have sex with men, pelvic inflammatory disease, *Chlamydia trachomatis*, HIV

Date received: 5 July 2018; accepted: 14 December 2018

## Introduction

Fitz-Hugh–Curtis syndrome (FHCS) is an inflammation of the liver capsule and the local peritoneum of the right upper abdominal quadrant (RUQ), which occurs in about 5%–15% cases of pelvic inflammatory disease and is usually seen in women of childbearing age.<sup>1</sup> This syndrome was first reported by Curtis in 1930 in a female patient who suffered from gonococcal salpingitis.<sup>2</sup> In 1934, Fitz-Hugh reported three female patients who had severe RUQ pain and also suffered from gonococcal salpingitis.<sup>3</sup> FHCS is seldom reported in men,<sup>1</sup> most likely because men are rarely affected by pelvic inflammatory disease. Men are usually mentioned only as transmitters of the pathogen.<sup>4</sup>

*Neisseria gonorrhoeae* was originally considered to be the main pathogen, but it was later discovered that *Chlamydia trachomatis* also plays an important role.<sup>5,6</sup> The infection is usually spread *per continuitatem*<sup>7</sup> through the right paracolic space, by blood or by lymphatic fluid,<sup>8,9</sup> selectively affecting the liver capsule.<sup>7</sup> The inflammation results in the formation of gentle fibrin adhesions ('violin strings') between the

surface of liver, diaphragm, and the abdominal wall, which causes RUQ pain, a characteristic symptom of FHCS. White cells count and liver function tests are usually normal or slightly elevated.<sup>1,7,10</sup> The C-reactive protein (CRP) is usually elevated,<sup>7</sup> and the erythrocyte sedimentation rate (ESR) is increased. The main diagnostic procedure is multi-slice computerized tomography (MSCT),<sup>11</sup> which reveals hepatic capsule contrast enhancement in the arterial phase,<sup>12</sup> while the morphology of liver remains intact. We can detect the pathogen by *nucleic acid amplification tests* (NAAT)<sup>8</sup> from cervical or rectal swab. The definite diagnosis is possible only by directly visualizing perihepatic adhesions by laparotomy or laparoscopy, which are not desirable in most cases

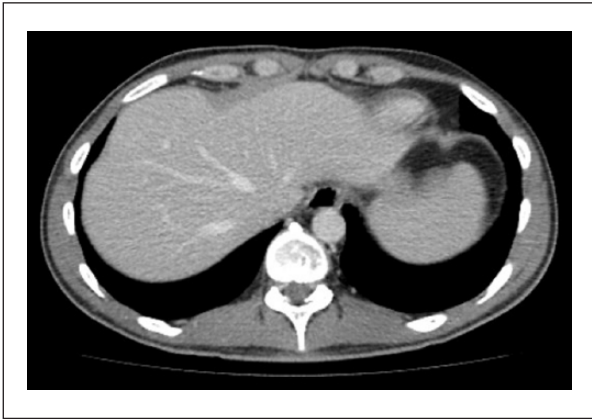
<sup>1</sup>University Hospital for Infectious Diseases 'Dr. Fran Mihaljević', Zagreb, Croatia

<sup>2</sup>School of Medicine, University of Zagreb, Zagreb, Croatia

### Corresponding Author:

Iva Lisičar, University Hospital for Infectious Diseases 'Dr. Fran Mihaljević', Mirogojska cesta 8, 10000, Zagreb, Croatia.  
Email: iva\_lisicar@yahoo.com



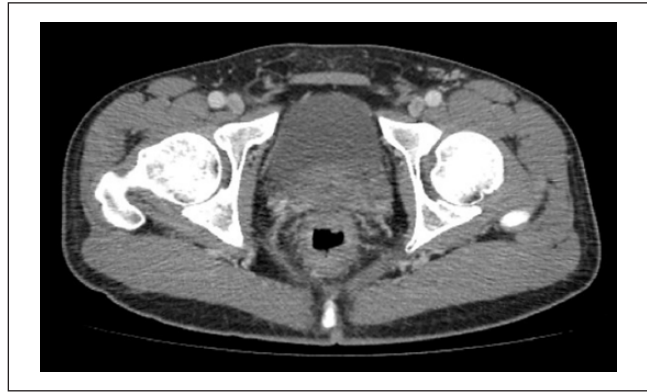

**Figure 1.** MSCT of the abdomen shows a normal-sized liver without focal lesions, with enhancement of the hepatic capsule and thickening of perihepatic fat.

due to their invasiveness. Thus, the diagnosis is most often made indirectly, by eliminating other, more frequent causes of RUQ pain,<sup>13,14</sup> for example, biliary colic, acute cholecystitis, hepatitis, liver abscess, subphrenic abscess, or acute pyelonephritis. The treatment is usually conservative,<sup>7,8,13</sup> and if it is initiated early and targeted at the causative microorganism, it leads to the complete resolution of symptoms. Severe cases may require laparoscopic adhesiotomy.<sup>1</sup>

### Case report

A 33-year-old HIV-infected patient was admitted to our hospital in September 2015. He was complaining about purulent and bloody anal discharge, slight RUQ pain, and low-grade fever that had started a month ago. A few days prior to his admittance to the Unique Health Identification (UHID), he noticed redness, swelling, and pain in his right heel. He had been on tenofovir/emtricitabine and efavirenz since HIV was diagnosed in October 2013. He acquired HIV infection through sex with other men (men who have sex with men (MSM)). His last CD4+ count in May 2015 was  $>500/\text{mm}^3$  and viral load (VL) undetectable. He stated that he had had an unprotected receptive anal intercourse few weeks prior to the onset of symptoms. On admission, the patient had a fever of  $37.8^\circ\text{C}$ , he was pale, and ill-appearing. There was noticeable redness and swelling below the lateral malleolus of the left ankle. On abdominal palpation, RUQ tenderness was noticed, without liver enlargement. The digital rectal exam showed purulent and bloody discharge. Laboratory test showed moderately elevated CRP  $77\text{ mg/L}$ , with normal complete blood count, biochemistry and liver function tests, urinalysis, and chest X-ray. Two sets of blood cultures for routine bacterial cultures were taken, as well as throat and rectal swabs for NAAT for *C. trachomatis* and *N. gonorrhoeae*. The patient was initially given intravenous ceftriaxone 1 g QD, oral doxycycline 100 mg BID, and indomethacin 25 mg TID. An



**Figure 2.** MSCT of the pelvis shows circularly thickened rectal wall with blurred surrounding fatty tissue.

abdominal ultrasound showed normal sized liver without focal lesions; 3 days after admission, the NAAT from rectal swab came back was positive for *C. trachomatis*. Hereafter, the treatment was continued with doxycycline and indomethacin only. An MSCT of the abdomen and pelvis showed a normal sized liver without focal lesions, with enhancement of the hepatic capsule and thickening of perihepatic fat (Figure 1). The rectal wall was circularly thickened with blurred surrounding fatty tissue (Figure 2). RUQ pain subsided about 5 days into treatment, as well as swelling and redness of the ankle. The patient was discharged after 10 days in good condition and with resolution of all symptoms. The doxycycline treatment was continued for 21 days. Although we were not able to determine the *C. trachomatis* serovar due to loss of sample in laboratory, the treatment duration was adjusted for potential lymphogranuloma venerum (LGV) infection, which can sometimes lead to severe proctitis or proctocolitis.<sup>15</sup>

### Discussion

FHCS was first described in a male patient in 1970.<sup>16</sup> Later on, a few authors also described perihepatitis in male patients with gonococcal urethritis,<sup>17</sup> proctitis,<sup>18</sup> and disseminated gonococcemia.<sup>19</sup> In 1981, Fung and Silpa<sup>18</sup> first described FHCS in an MSM. In 1985, Winkler et al.<sup>20</sup> first mentioned perihepatitis in an MSM patient with impaired cellular immunity, but it was considered to be related to an acute cytomegalovirus infection. In some reports, the etiology was not established, but the imaging methods of the abdomen showed liver capsule enhancement<sup>1,9</sup> or the adhesions were directly visualized by laparoscopy.<sup>21</sup>

None of these reports mentioned *C. trachomatis* as the causative agent of FHCS. So far, it has only been described in female patients. Our patient had symptoms consistent with proctitis and a pelvic inflammation, *C. trachomatis* confirmed from rectal swab, and an MSCT scan showing thickening of the rectal wall and perirectal fluid collection, indicating a local inflammatory process. Since his VL was

undetectable and CD4+ lymphocytes count normal, he was not immunocompromised, nor was he considered at greater risk for that matter.

Our main limitation is that the diagnosis was not directly confirmed with laparoscopy or laparotomy, but only indirectly, with MSCT. Also, we were unfortunately not able to determine *C. trachomatis* serovar due to the loss of sample in the laboratory.

Previous research shows that MSM exhibits higher rates of unprotected sex and consequently have a higher prevalence of sexually transmitted infections (STIs) than their non-MSM counterparts.<sup>22,23</sup> Furthermore, by practicing anal intercourse, they do not necessarily develop a typical symptom of STI, urethral discharge, which is why they fail to recognize it early enough. Late presentation to care increases the risk for the pathogen to advance, cause damage to surrounding structures, or lead to a systemic inflammation. Due to impaired cellular immunity, HIV-positive patients are at greater risk of developing a more severe disease.

## Conclusion

To our knowledge, FHCS has not yet been described in a male patient infected with HIV. We believe this matter is of importance because of its rare incidence in men, but probably more frequent in MSM. Failing to recognize it early enough could lead to chronic health issues. Also, we wish to highlight the importance of understanding the risk factors in MSM patients and having an increased index of suspicion when treating them, even more if they are infected with HIV.

## Acknowledgements

The authors declare there was not any other assistance taken.

## Declaration of conflicting interests

The author(s) declared no potential conflicts of interest with respect to the research, authorship, and/or publication of this article.

## Ethics approval

Our institution does not require ethical approval for reporting individual cases or case series.

## Funding

The author(s) received no financial support for the research, authorship, and/or publication of this article.

## Informed consent

Written informed consent was obtained from the patient for his anonymized information to be published in this article.

## ORCID iD

Iva Lisičar  <https://orcid.org/0000-0002-8396-909X>

## References

1. Yi H, Shim CS, Kim GW, et al. Case of Fitz-Hugh-Curtis syndrome in male without presentation of sexually transmitted disease. *World J Clin Cases* 2015; 3(11): 965–969.
2. Curtis HA. A cause of adhesions in the right upper quadrant. *JAMA* 1930; 94: 1221–1222.
3. Fitz-Hugh T. Acute gonococcal peritonitis of the right upper quadrant in women. *JAMA* 1934; 102: 2094–2096.
4. Workowski KA and Bolan GA. Sexually transmitted diseases treatment guidelines, 2015. *MMWR Recomm Rep* 2015; 64: 1–137.
5. Cusimano A, Abdelghany AMAB and Donadini A. Chronic intermittent abdominal pain in young woman with intestinal malrotation, Fitz-Hugh-Curtis Syndrome and appendiceal neuroendocrine tumor: a rare case report and literature review. *BMC Womens Health* 2016; 16: 3.
6. Marbet UA, Stalder GA, Vöggtlin J, et al. Diffuse peritonitis and chronic ascites due to infection with *Chlamydia trachomatis* in patients without liver disease: new presentation of the Fitz-Hugh-Curtis syndrome. *Brit Med J* 1986; 293(6538): 5–6.
7. Kazama I and Nakajima T. A case of Fitz-Hugh-Curtis syndrome complicated by appendicitis conservatively treated with antibiotics. *Clin Med Insights Case Rep* 2013; 6: 35–40.
8. You JS, Kim MJ, Chung HS, et al. Clinical features of Fitz-Hugh-Curtis syndrome in the emergency department. *Yonsei Med J* 2012; 53(4): 753–758.
9. Nardini P, Compri M, Marangoni A, et al. Acute Fitz-Hugh Curtis syndrome in a man due to gonococcal infection. *J Emerg Med* 2015; 48(3): 59–62.
10. Woo SY, Kim JI, Cheung DY, et al. Clinical outcome of Fitz-Hugh-Curtis syndrome mimicking acute biliary disease. *World J Gastroenterol* 2008; 14(45): 6975–6980.
11. Wang PY, Zhang L, Wang X, et al. Fitz-Hugh-Curtis syndrome: clinical diagnostic value of dynamic enhanced MSCT. *J Phys Ther Sci* 2015; 27(6): 1641–1644.
12. Muschart X. A case report with Fitz-Hugh-Curtis syndrome, what does it mean? *Acta Clin Belg* 2015; 70(5): 357–358.
13. Di Rocco G, Giannotti D, Collalti M, et al. Acute abdominal pain in a 24-year-old woman: Fitz-Hugh Curtis syndrome associated with pyelonephritis. *Clinics* 2012; 67(12): 1493–1495.
14. McSherry JA. *Chlamydia trachomatis* and the Fitz-Hugh-Curtis syndrome. *Can Fam Physician* 1985; 31: 1415–1416.
15. Bauwens JE, Lampe MF, Suchland RJ, et al. Infection with *Chlamydia trachomatis* lymphogranuloma venereum serovar L1 in homosexual men with proctitis: molecular analysis of an unusual case cluster. *Clin Infect Dis* 1995; 20(3): 576–581.
16. Kimball MW and Knee S. Gonococcal perihepatitis in a male. The Fitz-Hugh-Curtis syndrome. *N Engl J Med* 1970; 282(19): 1082–1084.
17. Francis TI and Osoba AO. Gonococcal hepatitis (Fitz-Hugh Curtis syndrome) in a male patient. *Brit J Vener Dis* 1972; 48(3): 187–188.
18. Fung GL and Silpa M. Fitz-Hugh and Curtis syndrome in a man. *JAMA* 1981; 245(2): 128.
19. Davidson AC and Hawkins DA. Pleuritic pain: Fitz Hugh Curtis syndrome in a man. *Brit Med J* 1982; 284(6318): 808.
20. Winkler WP, Kotler DP and Saleh J. Fitz-Hugh and Curtis syndrome in a homosexual man with impaired cell mediated immunity. *Gastrointest Endosc* 1985; 31(1): 28–30.

21. Rouhard S, Maldague P and Ramboux A. Fitz-Hugh-Curtis syndrome in a man. *Endoscopy* 2014; 46(Suppl 1 UCTN): E1.
22. Fenton KA and Imrie J. Increasing rates of sexually transmitted diseases in homosexual men in Western Europe and the United States: why? *Infect Dis Clin North Am* 2005; 19(2): 311–331.
23. Ciesielski CA. Sexually transmitted diseases in men who have sex with men: an epidemiologic review. *Curr Infect Dis Rep* 2003; 5(2): 145–152.