



## Središnja medicinska knjižnica

**Košec A., Vučić M., Bedeković V., Ivkić M. (2017) *Osteoblastic extraosseous osteosarcoma of the neck*. Journal of Oral and Maxillofacial Surgery, 75 (3). pp. 650.e1-e5. ISSN 0278-2391**

<http://www.elsevier.com/locate/issn/02782391>

<http://www.sciencedirect.com/science/journal/02782391>

<http://dx.doi.org/10.1016/j.joms.2016.11.008>

<http://medlib.mef.hr/2906>

University of Zagreb Medical School Repository

<http://medlib.mef.hr/>

## **Osteoblastic Extrasosseous Osteosarcoma Of The Neck**

**Andro Košec, MD<sup>a</sup>, Professor Majda Vučić, MD, PhD<sup>c</sup>, Professor Vladimir Bedeković, MD, PhD<sup>b</sup>, Professor Mirko Ivkić, MD, PhD<sup>b</sup>**

<sup>a</sup> Department of Otorhinolaryngology and Head and Neck Surgery, University Hospital Center Sestre milosrdnice, Vinogradska cesta 29, Zagreb, Croatia

<sup>b</sup> School of Medicine, University of Zagreb, Šalata 3b, Zagreb, Croatia

<sup>c</sup> Department of Pathology Ljudevit Jurak, University Hospital Center Sestre milosrdnice, Vinogradska cesta 29, Zagreb, Croatia

*Author correspondence:*

Andro Košec, MD

Department of Otorhinolaryngology and Head and Neck Surgery, Clinical Hospital Center Sestre milosrdnice, Vinogradska cesta 29, Zagreb, Croatia

Phone: +385 1 3787108, Fax: +385 13769067

e-mail: andro.kosec@yahoo.com

## **Abstract**

Extrasosseous osteosarcoma as a primary tumor of the neck is exceedingly rare, with only several cases reported to date. Most appropriate therapy is still under investigation. We report a case of an aggressive right-sided advanced stage extrasosseous osteosarcoma in a female patient. A 48-year-old woman presented with a right-sided infra-parotid mass encompassing neck regions II and III, measuring over 6 centimeters in cranio-caudal diameter. She was initially treated by wide surgical resection. The definitive histopathological diagnosis was osteoblastic extrasosseous osteosarcoma. Computer tomography at initial presentation did not show signs of tumorous growth in other areas. The patient was treated with adjuvant chemoradiotherapy postoperatively. A local recurrence with intra-spinal propagation was noted 4 months after surgery and a second surgical attempt was made to remove the tumor. The disease recurred in the neck and spine 3 months after the second surgery and a final, unsuccessful attempt at reducing the tumor mass was performed. The tumor site was re-irradiated. The patient died three months later due to local disease propagation. Extrasosseous osteosarcoma of the neck is an extremely rare tumor, distinct from primary osteosarcoma of the bone, with a high rate of local recurrence and poor prognosis in advanced disease.

**Keywords:** head and neck; osteoblastic extrasosseous osteosarcoma; radiotherapy; recurrence; surgery

## **Introduction**

Osteosarcoma, the most common malignancy of the bone, frequently occurs in the extremities, with 10% of cases originating in the head and neck region. [1] Extrasosseous osteosarcoma of the head and neck is a very rare malignant tumor that comprises but 1% of all soft tissue sarcomas with exceedingly rare occurrence in the head and neck. [2,3,4,5,6] Very few cases of extrasosseous osteosarcoma in the neck have been described to date, data indicating that its behavior and response to treatment differs from conventional osseous osteosarcoma. [7,8,9,10] This article describes a case of advanced stage right-sided extrasosseous osteosarcoma of the neck and discusses similar cases with respect to possible differential diagnoses and available treatment modalities.

## **Case report**

A 48-year-old female patient was admitted to our department due to rapid growth of a right-sided infraauricular and infaparotid mass encompassing neck regions II and III, over 6 centimeters in cranio-caudal diameter, producing light pain and discomfort through the period of several months prior to examination. Her medical history was burdened with progressive multiple sclerosis causing urinary incontinency and paraparesis. She had been previously treated with immunoglobulin and immunosuppressants that were discontinued due to disease symptom improvement.

Neck ultrasound examination was performed at the time of initial symptom presentation and an inhomogeneous, calcified, well defined nodule measuring up to 4 cm was found laterally

to the mandible neck on the right side. Nasofiberoendoscopy was unremarkable. Fine needle aspiration cytological examination suggested a possible pleomorphic adenoma of the parotid gland. Since the mass continued to increase in size, surgical treatment was planned and preoperative magnetic resonance imaging showed a large, polycystic and inhomogeneous tumor mass descending toward the thyroid gland, compressing the carotid artery and internal jugular vein and causing slight contralateral tracheal displacement. Tumor tissue adhered to the carotid sheath and possible vertebral involvement was noted in vertebral foramina C4 and C5. (Fig. 1, 2, 3)

A complete tumor resection alongside a wide margin of tissue encompassing muscles of the prevertebral, parapharyngeal and retropharyngeal space was performed. Possible lysis of lateral vertebral processes C4 and C5 was noted, and the resection margins were widened intraoperatively, after neurosurgical consultation.

The definitive histopathological result was osteoblastic extrasosseal osteosarcoma with malignant osteoid and chondroid matrix elements arranged in atypical formations. The tumor cells showed hyperchromatic nuclei, atypical mitoses and were positive for vimentin and negative for cytokeratin AE1/AE3. Ki-67 proliferation index was 80%. No attachment to bone or periosteum or evidence of mixed mesenchymal tumor characteristics were found. (Fig. 4, 5)

The postoperative course was uneventful and a multidisciplinary tumor board gave a recommendation for adjuvant chemoradiotherapy.

A follow up computed tomography scan one month after surgery showed residual tumor tissue involving the retropharyngeal and prevertebral space medially and laterally to the right of the C2 vertebrae reaching the level of the hypopharynx caudally with possible contralateral

extension. It infiltrated the right side of the epiglottis with compression of the supraglottic airway. It showed intraspinal propagation in levels C3-C5. (Fig. 6)

Radiotherapy (60 Gy) with concomitant Doxorubicin and cis-platinum treatment were administered with limited initial tumor regression and further subsequent spinal infiltration recorded. (Fig. 7) Two further surgical attempts at reducing the tumor mass were made 5 months and 7 months after the initial surgery with a combined neurosurgical and head and neck surgical team approach, but the patient's condition continued to deteriorate. She subsequently underwent tracheostomy, palliative radiotherapy (30 Gy), intensive care treatment and mechanical ventilation due to neurologic deterioration and was discharged to a palliative institution where she died three months after being discharged from the intensive care unit.

## **Discussion**

Osteoblastic extraosseal osteosarcoma of the head and neck is an exceedingly rare tumor, with available literature reports of only 8 cases involving the neck. (Table 1) This patient had no previous history of local trauma or radiotherapy, which are factors commonly connected with most of the previously described case reports. [6]

A common diagnostic pitfall is failing to achieve adequate surgical removal in advanced stage disease due to an indolent clinical course in early-stage disease, with often misleading results of ultrasound and cytological examinations. The tumor often mimics a reactive lymph node, or a benign lesion, as was the case with our patient. Other differential diagnoses include myositis ossificans, calcified lymph nodes that can be associated with granulomatous inflammatory disease and pilomatrixoma. [8,9]

Data show that fine needle aspiration cytology or biopsy cannot produce a reliable diagnosis, with excisional biopsy remaining the golden standard in confirming the diagnosis. [11] Previous reports state that one-fourth of cases appear encapsulated in gross appearance, but upon histopathologic examination, all of the tumors penetrate their pseudocapsule and infiltrate adjacent structures. [8] The tumor was considered as a primary since no similar tumor were recorded throughout the entire course of treatment in the head and neck region.

Available data on treatment recommendations emphasize the importance of timely surgical intervention with adjuvant radiotherapy. [12] Recent review studies on a virtually all reported cases show that 88% of patients have locally advanced disease (stage III) according to the AJCC staging system upon initial diagnosis, and 50% develop local recurrences after surgical removal with wide margins. [13] Extrasosseous osteosarcoma's characteristic local recurrence rate is even higher patients with tumors exceeding 5 cm in diameter, which is considered an independent adverse prognostic factor. [8,14,15] Literature reports 5-year disease specific survival rates ranging from 25 to 46%, mostly due to invasive local recurrence and lung metastases occurring in the first postoperative year in 60% of patients. Chemotherapy treatment has shown limited success, with only 13 to 15% of patients responding to treatment.

It seems that extrasosseous osteosarcoma's biologic behavior and response to therapy share more traits with high-grade soft tissue sarcomas than with osseous osteosarcoma, especially with regard to median patient age of presentation, anatomic distribution and chemoresistance. [12,14]

## **Conclusion**

Osteoblastic extraosseous osteosarcoma of the neck is an exceedingly rare malignancy that encompasses less than 1% of all head and neck soft tissue sarcomas. It is difficult to diagnose, often times being mistakenly labeled a benign tumor in its early stage, but requires extensive surgery in moderate and advanced disease stages. It is clinically and therapeutically distinct from osseous osteosarcoma, and is marked by a high rate of local recurrence and low disease-specific survival.

## **Disclosure of Interest:**

The authors have no conflict of interest to declare.



## References

- [1] Clark L, Unni KK, Dahlin DC. Osteosarcoma of the jaw. *Cancer* 51:2311–6, 1983
- [2] Luna-Ortiz K, Ortega-Gutierrez C, Dominguez-Malagon H, et al. Extrasosseous osteosarcoma in the neck. *Auris Nasus Larynx* 39(3):333-6, 2012
- [3] Hatano H, Morita T, Kobayashi H, et al. Extraskkeletal osteosarcoma of the jaw. *Skeletal Radiol* 34:171–5, 2005
- [4] Jacob R, Abraham E, Jyothirmayi R, et al. Extraskkeletal osteosarcoma of the orbit. *Sarcoma* 2:121–4, 1998
- [5] Massi D, Franchi A, Leoncini G, et al. Primary cutaneous osteosarcoma of the scalp: a case report and review of the literature. *J Cutan Pathol* 34:61–4, 2007
- [6] Saito Y, Miyajima C, Nakao K, et al. Highly malignant submandibular extraskkeletal osteosarcoma in a young patient. *Auris Nasus Larynx* 35:576–8, 2008
- [7] Chung EB, Enzinger FM. Extraskkeletal osteosarcoma. *Cancer* 60:1132–1142, 1987
- [8] Bane BL, Evans HL, Ro JY, et al. Extraskkeletal osteosarcoma. A clinic-pathologic review of 26 cases. *Cancer* 65:2762–70, 1990
- [9] Stimson PG, Valenzuela-Espinoza A, Tortoledo ME, et al. Primary osteosarcoma of the parotid gland. *Oral Surg Oral Med Oral Pathol.* 68(1):80-6, 1989
- [10] Smeele LE, Coste´ense PJ, van der Waal I, et al. Effect of chemotherapy on survival of

craniofacial osteosarcoma: a systematic review of 201 patients. *J Clin Oncol* 15:363–7, 1997

[11] Nicol KK, Ward WG, Savage PD, et al. Fine-needle aspiration biopsy of

skeletal versus extraskeletal osteosarcoma. *Cancer* 84:176–85, 1998

[12] Ahmad SA, Patel SR, Ballo MT, et al. Extrasosseous osteosarcoma: response to treatment and long-term outcome. *J Clin Oncol* 20(2):521-7, 2002

[13] Edge SB, Byrd DR, Compton CC, et al. *AJCC Cancer Staging Manual*. 7th ed. New York,

NY: Springer; 2010

[14] Fan Z, Patel S, Lewis VO, et al. Should High-grade Extrasosseous Osteosarcoma Be Treated With Multimodality Therapy Like Other Soft Tissue Sarcomas? *Clin Orthop Relat Res* 473(11):3604-11, 2015

[15] Granados-Garcia M, Luna-Ortiz K, Castillo-Oliva HA, et al. Free osseous and soft tissue surgical margins as prognostic factors in mandibular osteosarcoma. *Oral Oncol* 42:172–6, 2006

## Tables and legends

Table 1. Demographic characteristics, localization, histopathologic subtype and follow-up of previously reported head and neck extrasosseous osteosarcomas.

Source	Luna-Ortiz et al. <sup>2</sup>	Hatano et al. <sup>3</sup>	Saito et al. <sup>6</sup>	Stimson et al. <sup>9</sup>	Our Case
Age (years)	74	25	17	63	48
Sex	Female	Male	Male	3 Male, 1 female	Female
Localization	Right submandibular	Right mandibular angle	Left submandibular	Parotid	Right neck
Tumor diameter	12 cm	1.5 cm	6.5 cm	3-6 cm	6 cm
Follow up	Died within one year	Disease-free, 2 years	Died of recurrence 1 year after treatment	Three died of metastatic disease within 2 years, one lost to follow-up	Died of metastatic disease 1 year after treatment
Treatment	Surgery and palliative radiotherapy	Surgery, chemoradiotherapy	Surgery, chemoradiotherapy	Surgery	Surgery, chemoradiotherapy

## Figure captions

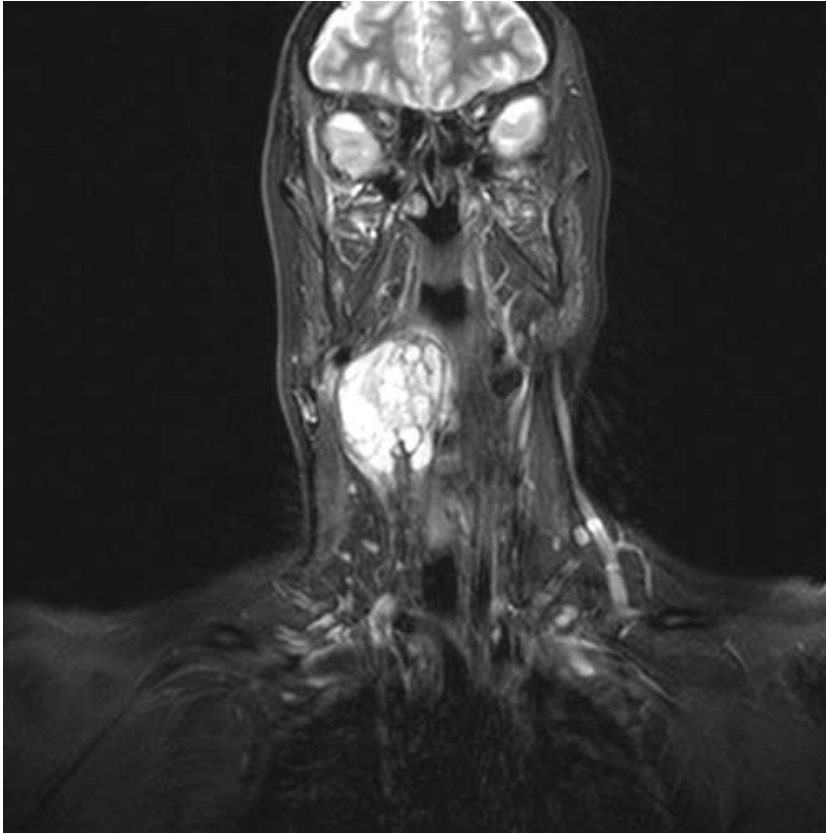


Fig. 1. Axial MRI T2 weighted scan showing a large, polycystic and inhomogeneous tumor mass causing slight contralateral tracheal dislodgement.

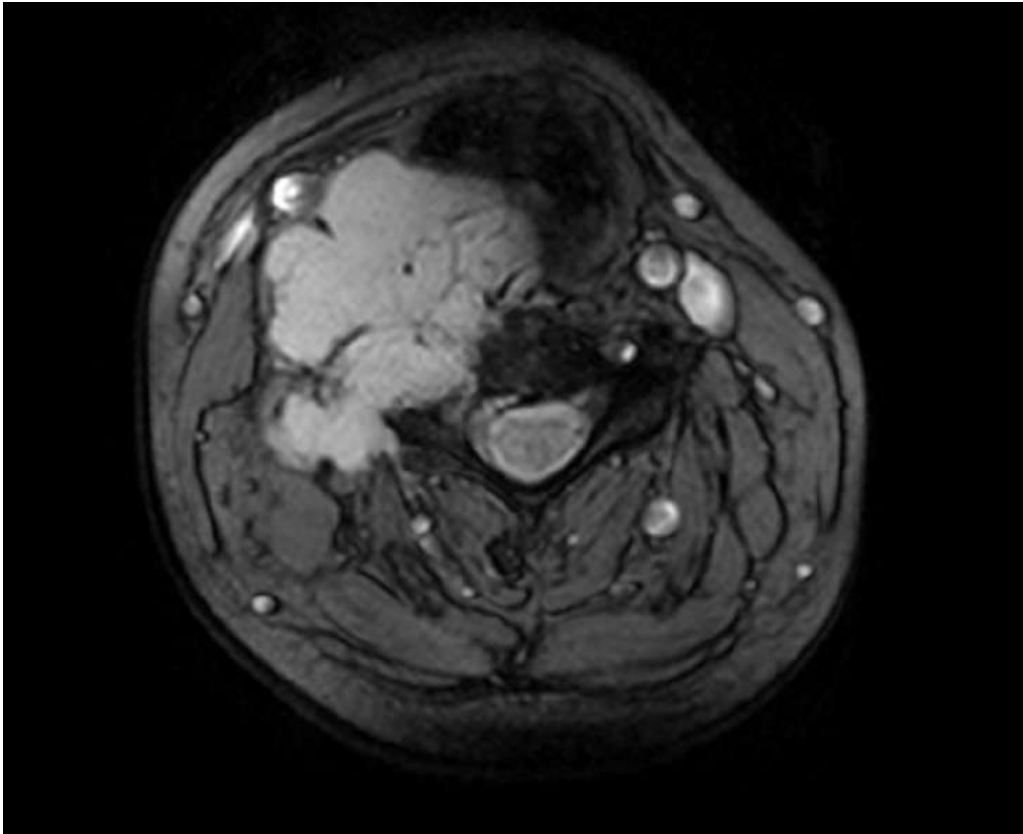


Fig. 2. Coronal MRI T2 weighted scan prior to initial surgery showing the tumor mass compressing the carotid artery and internal jugular vein.

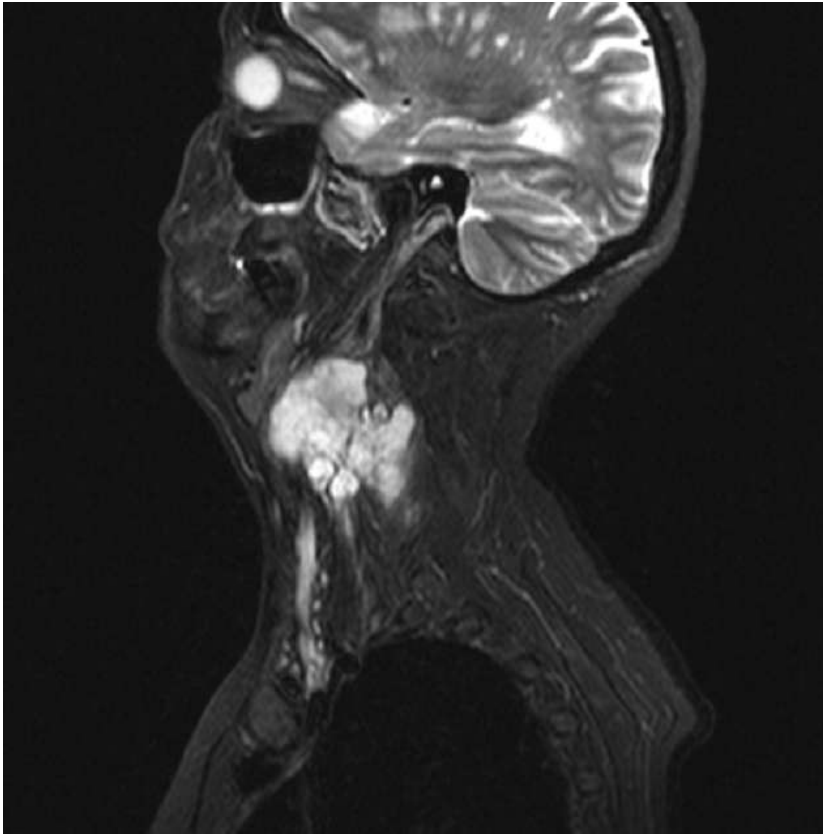


Fig. 3. Sagittal MRI T2 weighted scan showing the tumor position with regard to the spine.

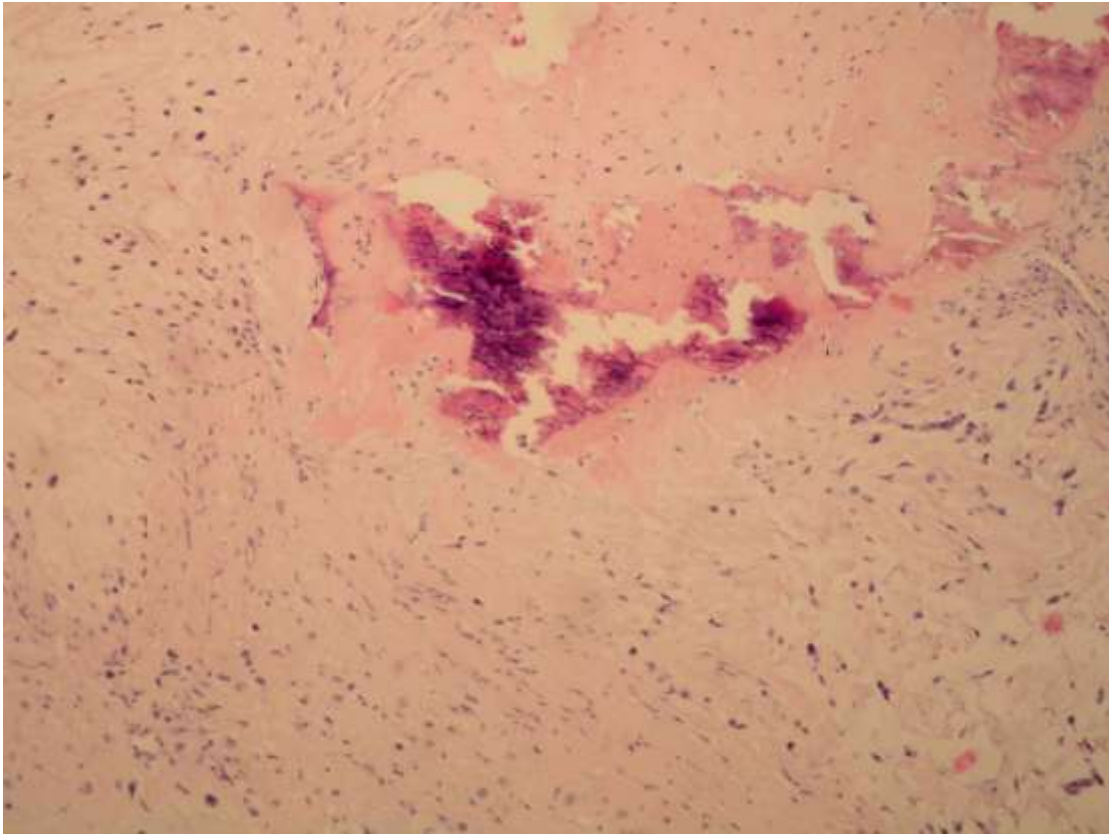


Fig. 4. Definitive histopathological result confirming primary osteoblastic extrasosseal osteosarcoma with malignant osteoid elements arranged in atypical formations. (HE, 100x)

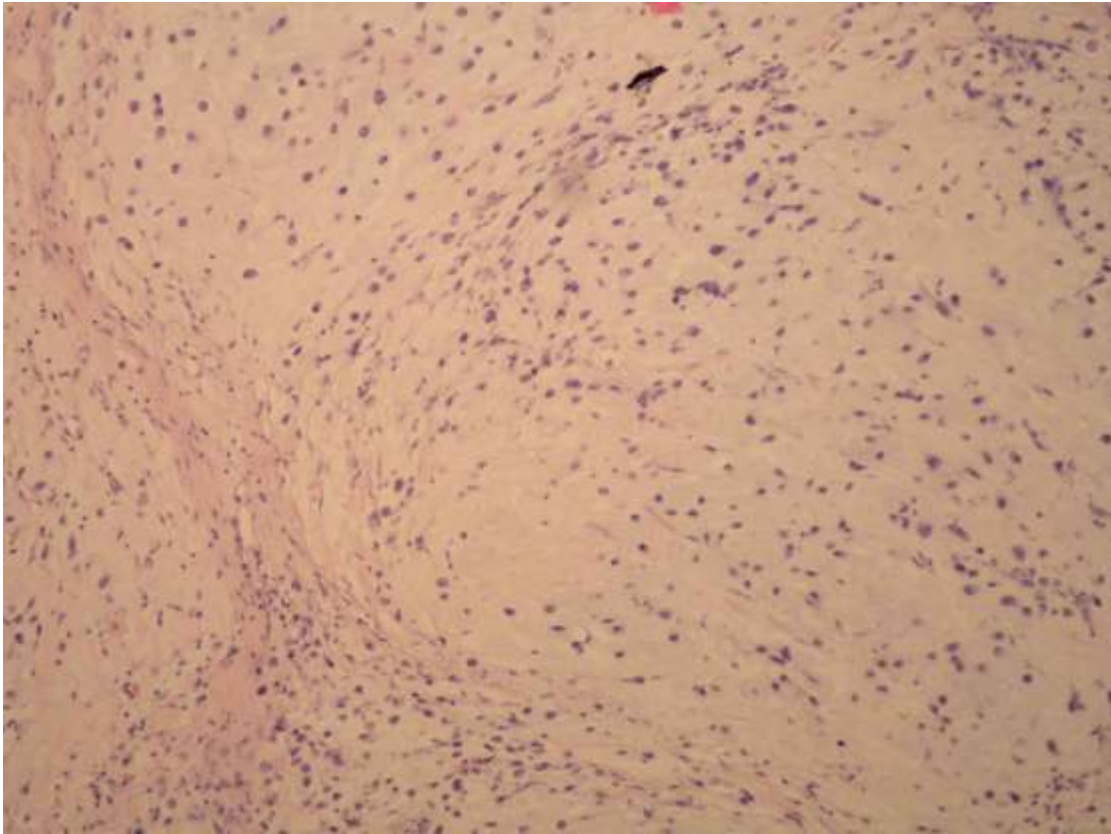


Fig. 5. The tumor cells show abundant chondroid matrix, hyperchromatic nuclei and numerous atypical mitoses. (HE, 200x)



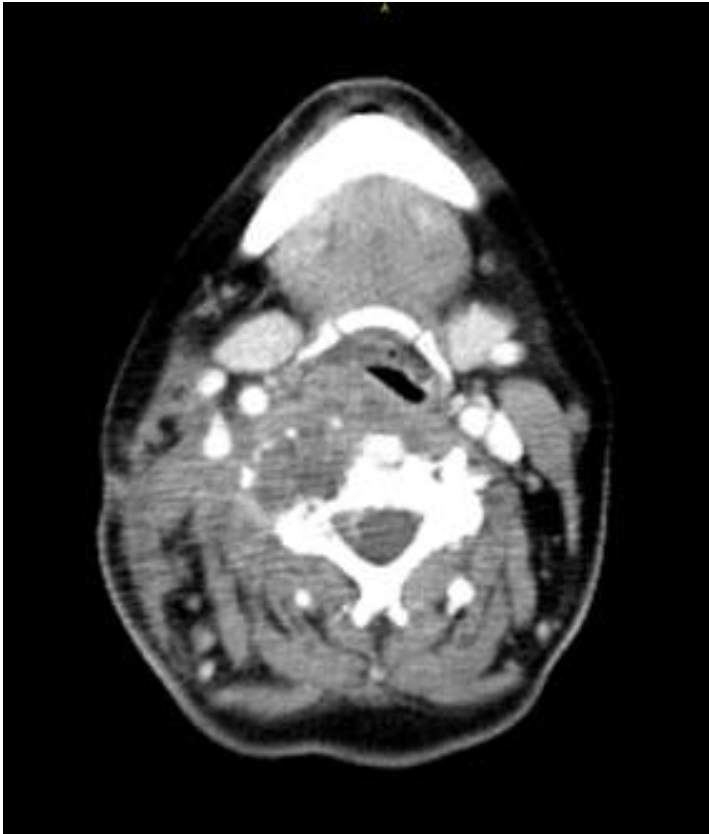

Fig. 6. Residual tumor involving the retropharyngeal and prevertebral space medially and laterally to the right of the C2 vertebrae reaching the level of the hypopharynx caudally.

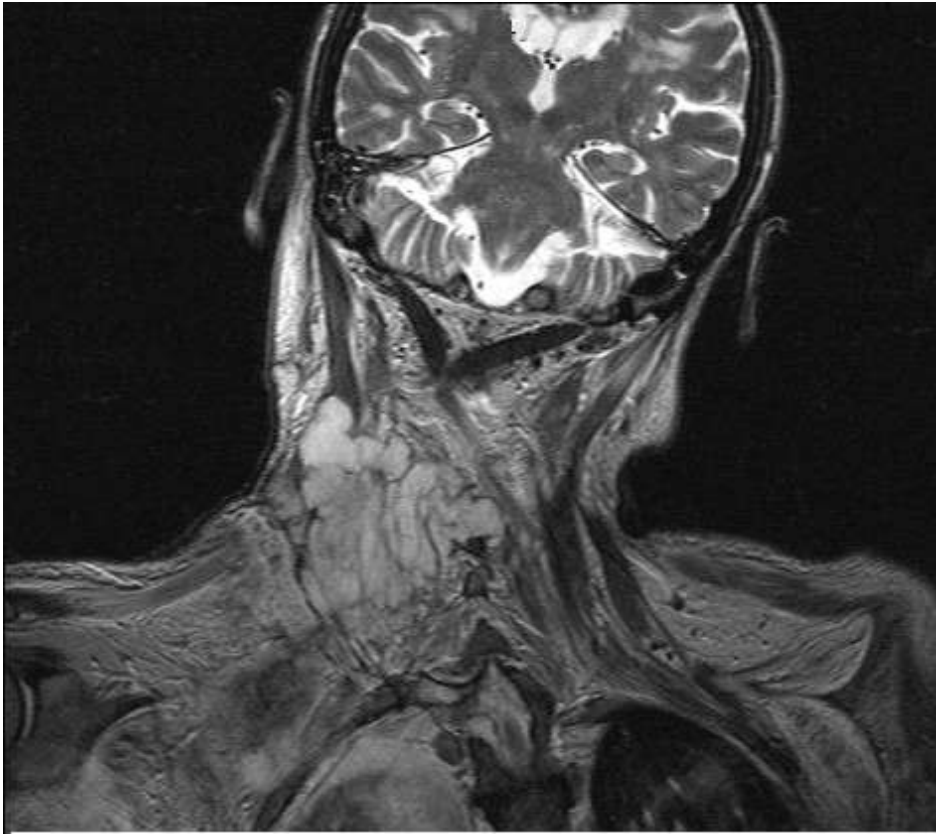


Fig. 7. Residual tumor after adjuvant chemoradiotherapy infiltrating the vertebrae and extending into the spinal channel.