



Središnja medicinska knjižnica

Bogović M., Papeš D., Mitar D., Smiljanić R., Sršen-Medančić S., Čavar S., Antabak A., Luetić T. (2016) *Abdominal aortic thrombosis in a healthy neonate. Annals of Vascular Surgery*, 32. pp. 131.e7-9. ISSN 0890-5096

<http://www.elsevier.com/locate/issn/08905096>

<http://www.sciencedirect.com/science/journal/08905096>

<http://dx.doi.org/10.1016/j.avsg.2015.10.014>

<http://medlib.mef.hr/2727>

University of Zagreb Medical School Repository

<http://medlib.mef.hr/>

Abdominal aortic thrombosis in a healthy neonate

Authors

Marko Bogović, Dino Papeš, Davorin Mitar, Ranko Smiljanić^a, Suzana Sršen-Medančić, Stanko Čavar, Anko Antabak, Tomislav Luetić

Institution

Department of surgery

^a Department of radiology

Clinical Hospital Center Zagreb

Kišpatičeva 12, 10000 Zagreb, Croatia

Corresponding author

Dino Papeš, MD

Department of surgery

Clinical Hospital Center Zagreb

Kišpatičeva 12, 10000 Zagreb, Croatia

e-mail: dinopapes@gmail.com

phone: 00385981620627

Abstract

Abdominal aortic thrombosis is a rare entity in neonates and has mostly been associated with umbilical artery or cardiac catheterization. We present a complicated case of an otherwise healthy neonate who developed thrombosis of abdominal aorta with renal failure. Therapy with intravenous heparin was unsuccessful and thrombolysis was contraindicated because of disseminated intravascular coagulation so we decided to perform open thrombectomy using the left retroperitoneal approach. The following day, thrombosis recurred in the same extent and despite high risk of bleeding Alteplase was eventually given, which resulted in recanalization of the aorta 6 hours later. Renal function recovered, dialysis was discontinued, and further course was uneventful. The treatment of abdominal aortic thrombosis in neonates should be considered on a case-by-case basis because the available data on the condition is limited to case report and series. If open thrombectomy is performed, retroperitoneal approach should be preferred because it allows for easy institution of peritoneal dialysis should the need arise.

Keywords

Abdominal aorta, thrombosis, neonate, aortic thrombectomy, thrombolysis

Introduction

Abdominal aortic thrombosis is a rare entity in neonates. It is a recognized complication of umbilical artery cannulation or cardiac catheterization [1]. We present a complicated case of an otherwise healthy neonate who developed thrombosis of the abdominal aorta with subsequent renal failure and required multimodal treatment.

Case presentation

The patient was a 3.57 kg neonate born from normal pregnancy at term by vaginal delivery. On the third day he developed lower extremity cyanosis followed by respiratory distress, anuria, and diminished femoral pulses. D-dimer level was elevated at 5.0 mg/L. Echocardiography showed normal heart with no coarctation. Abdominal ultrasound with Doppler revealed no flow through abdominal aorta. Intravenous heparin bolus of 100 units/kg over 10 min followed by 28 units/kg/h was given. CT aortography was ordered and showed thrombotic occlusion of the abdominal aorta from the level of celiac trunk (which was patent) extending to both common iliac arteries (Figure 1). Both renal arteries ostia were occluded. Superior mesenteric artery was perfused through collateral network. Both common femoral arteries were collaterally perfused through epigastric arteries (Figure 2). Due to worsening renal function, no improvement to heparin therapy, and development of disseminated intravascular coagulation (DIC), peritoneal dialysis (CAPD) was instituted and the decision to undergo open thrombectomy was made. We used left retroperitoneal approach through a flank incision (Figure 3). A 5 mm transverse arteriotomy was made in the segment between inferior mesenteric artery and bifurcation followed by proximal and distal thrombectomy using Fogarty catheter

(Figure 4). Good inflow and backflow were obtained and arteriotomy was closed with Prolen 7-0 suture. The following day control Doppler showed recurrent thrombotic occlusion in the same extent as previous. Due to the worsening condition of the child Alteplase 0.5 mg/kg/h infusion was given despite high risk of bleeding. After 6 hours Doppler showed recanalization of the aorta, Alteplase was discontinued and intravenous heparin 28 units/kg/h was given and further titrated to aPTT between 50-80 s. After 5 days anticoagulation was converted to LMWH (enoxaparin 1 mg/kg subcutaneously every 12 hours). Renal function recovered within several days and dialysis was discontinued. Patient was discharged after 5 weeks and further course was uneventful. Prevention of thrombosis included good hydration with preclusion of dehydration, and Aspirin prophylaxis for 1 year postoperatively in dose of 1 mg/kg. Detailed workup found no underlying cause of the thrombosis.

Discussion

Possible causes of abdominal aorta thrombosis and thromboembolism in neonates include umbilical artery catheterization, cardiac catheterization, peripartum asphyxia, Takayasu arteritis, Kawasaki disease, severe dehydration, septicemia or embolism from congenital heart defects [1,2]. Another possible cause is birth trauma due to rough handling during or after delivery.

The treatment of neonatal abdominal aortic thrombosis is considered on a case-by-case basis because the published data on the condition is limited to case report and series. In asymptomatic cases, observation may be sufficient. In symptomatic cases, anticoagulation with heparin or LMWH and thrombolysis with tissue plasminogen activator has been used [2-4]. Surgical thrombectomy is an aggressive but successful

option that can be done by a transperitoneal approach through midline laparotomy, or by a retroperitoneal approach through a flank incision [5]. The advantage of the retroperitoneal approach is that, in most cases, entering the abdomen is avoided so CAPD can be performed (provided the intestine is sufficiently perfused) if the need arises [5]. Percutaneous transcatheter thrombectomy is an additional technique for the treatment of neonatal arterial thrombosis available in some centers [6] and local thrombolysis can also be added notwithstanding DIC. Although this is a less-invasive alternative to open thrombectomy, our center has no experience with that technique in neonates so we proceeded with surgery.

Our patient was transferred to our neonatal ICU with advanced renal failure requiring CAPD. Since there was no improvement to heparin therapy, and Alteplase was contraindicated because of DIC, we decided to perform open thrombectomy. The following day thrombosis recurred in the same extent, and the condition of the child worsened so Alteplase was eventually given as a last resort.

To conclude, the treatment of thrombosis of the abdominal aorta in a neonate should be considered on a case-by-case basis and may include several treatment options or their combinations in complicated cases. If open thrombectomy is performed, retroperitoneal approach should be preferred because it allows for easy institution of peritoneal dialysis should the need arise.

References

1. de Godoy JM, De Marchi CH, Silva MG, Carvalho MC, Moscardini A, Medeiros JC. Thrombosis of the abdominal aorta in a newborn: case report and review of literature. *J Pediatr Surg* 2003;38:E11.
2. Hartmann J, Hussein A, Trowitzsch E, Becker J, Hennecke KH. Treatment of neonatal thrombus formation with recombinant tissue plasminogen activator: Six years experience and review of the literature. *Arch Dis Child Fetal Neonatal* 2011;85:18-22.
3. Edstrom CS, Christensen RD. Evaluation and treatment of thrombosis in the neonatal intensive care unit. *Clin Perinatol* 2000;27:623-41.
4. Klinger G, Hellmann J, Daneman A: Severe aortic thrombosis in the neonate - Successful treatment with low-molecular-weight heparin: Two case reports and review of the literature. *Am J Perinatol* 2000;17:151-8.
5. Lofland GK, Russo P, Sethia B, de Leval M. Aortic thrombosis in neonates and infants. *Ann Surg.* 1988;208:743-5.
6. Greenberg R, Waldman D, Brooks C, et al.: Endovascular treatment of renal artery thrombosis caused by umbilical artery catheterization, *J Vasc Surg.* 1998;28:949–53.

Figures

Figure 1. CT aortography showing thrombotic occlusion of the abdominal aorta from the level of celiac artery extending to both common iliac arteries. Both renal arteries ostia are occluded. Right kidney is edematous due to ischemia, and some collateral perfusion of the left kidney can be seen.

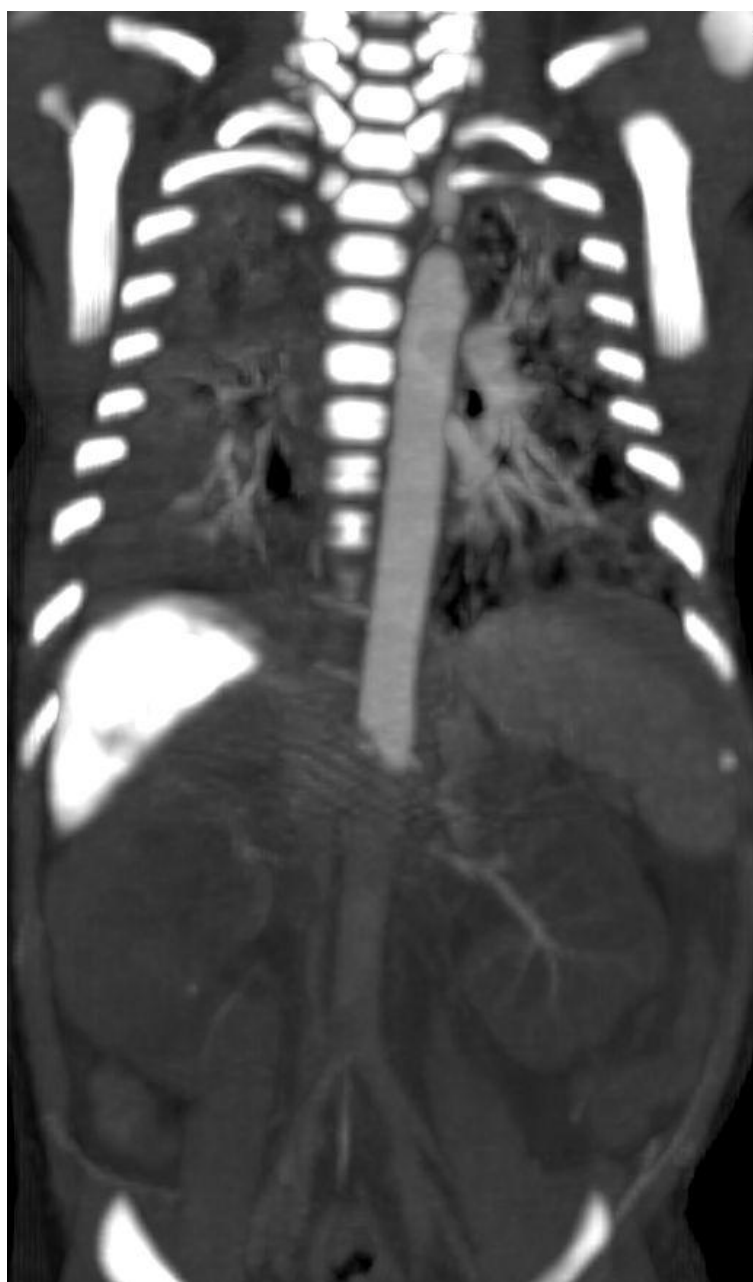

Figure 2. CT aortography showing that both common femoral arteries were collaterally perfused through superior and inferior epigastric arteries which prevented gangrene

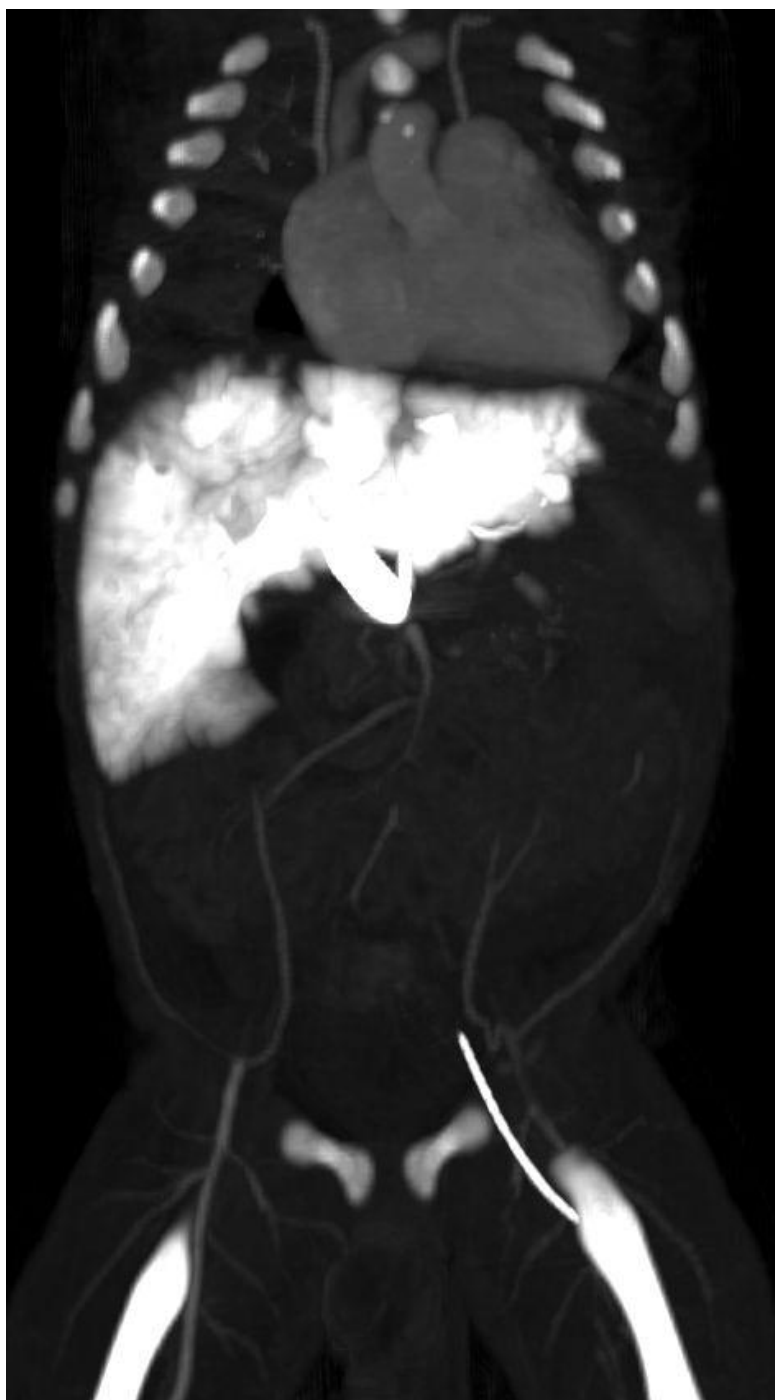

Figure 3. Infrarenal aorta was exposed by a left retroperitoneal approach through a flank incision. Isolated are inferior mesenteric artery (blue loop), left ureter (white loop), left common iliac artery (encircled by red loop) and right common iliac artery (encircled by white loop). Blue discoloration of the inferior aorta due to thrombosis is seen.

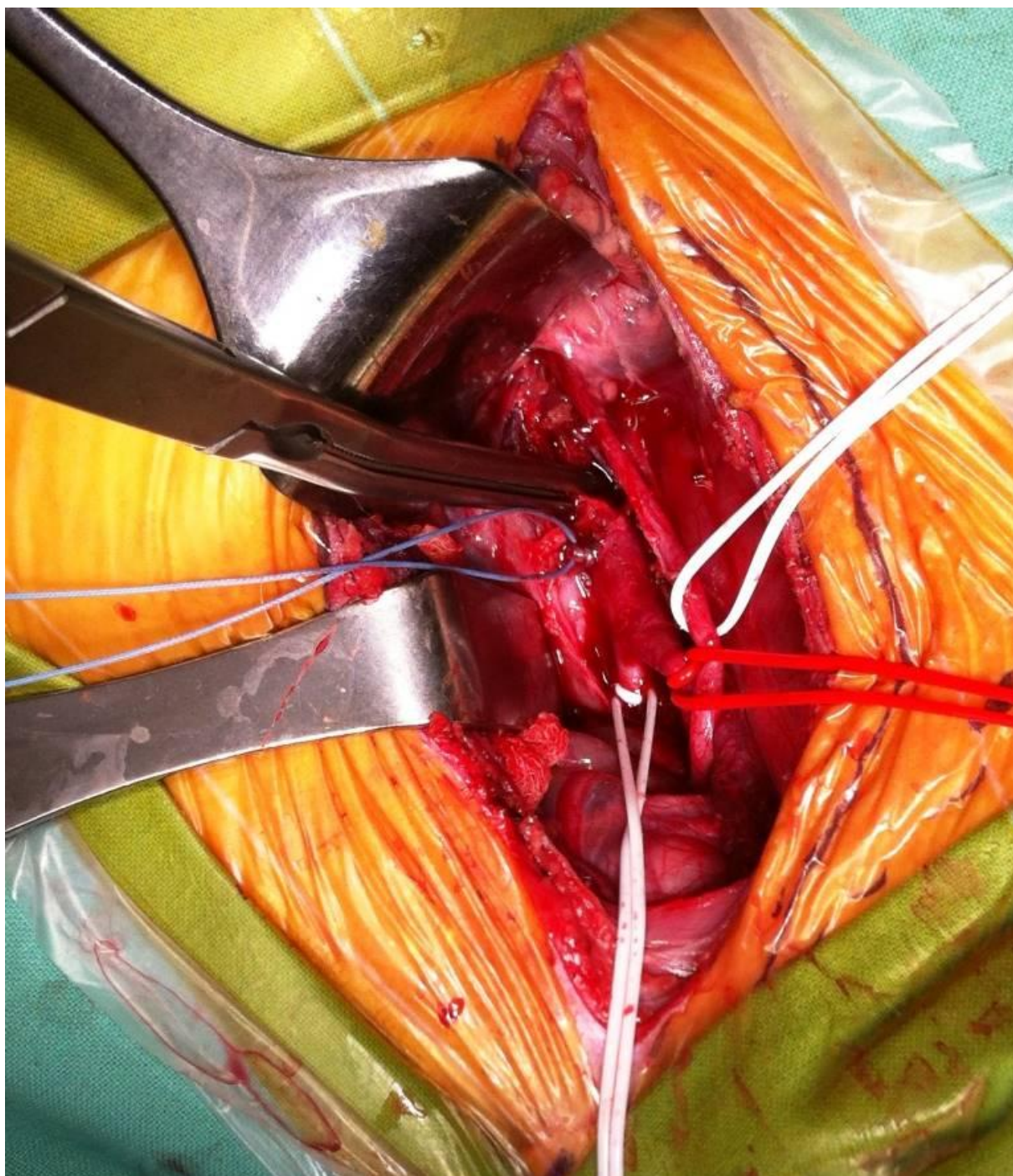


Figure 4. Thrombi obtained by proximal and distal thrombectomy using Fogarty catheter (right).

