



## Središnja medicinska knjižnica

**Petrović I., Pećin I., Prutki M., Augustin G., Nedić A., Gojević A., Potočki K., Reiner Z. (2015) *Thigh abscess as an extension of psoas abscess: the first manifestation of perforated appendiceal adenocarcinoma: case report. Wiener Klinische Wochenschrift, 127 (15-16). pp. 645-8. ISSN 0043-5325***

<http://www.springer.com/journal/508>

<http://link.springer.com/journal/508>

The final publication is available at Springer via  
<http://dx.doi.org/10.1007/s00508-014-0651-0>

<http://medlib.mef.hr/2407>

University of Zagreb Medical School Repository

<http://medlib.mef.hr/>

**Thigh abscess as an extension of psoas abscess - the first manifestation of perforated appendiceal adenocarcinoma: case report**

Igor Petrovic<sup>1</sup>, Ivan Pecin<sup>2</sup>, Maja Prutki<sup>3</sup>, Goran Augustin<sup>1</sup>, Ana Nedic<sup>4</sup>, Ante Gojevic<sup>1</sup>, Kristina Potocki<sup>3</sup>, Zeljko Reiner<sup>2</sup>

<sup>1</sup>Division of Abdominal Surgery, Clinical University Hospital Centre "Zagreb", Kispaticeva 12, 10000 Zagreb, Croatia

<sup>2</sup>Department of Internal Medicine, Clinical University Hospital Centre "Zagreb", Kispaticeva 12, 10000 Zagreb, Croatia

<sup>3</sup>Department of Radiology, Clinical University Hospital Centre "Zagreb", Kispaticeva 12, 10000 Zagreb, Croatia

<sup>4</sup>Department of Internal Medicine, General Hospital Virovitica, Gajeva 21, 33000 Virovitica

Corresponding author: Ana Nedic, MD

General Hospital „Virovitica“

Gajeva 21, Virovitica 33000

Croatia

Tel: +385-33-747444

Fax: +385-33-725323

E-mail: ana.nedic25@gmail.com

The article type: Case report and review of literature

## **ABSTRACT**

A 65 year-old female presented with a painful, swollen, red right thigh and the mild pain in the right abdomen without nausea, vomiting or diarrhoea that lasted for one week. Laboratory findings revealed elevated inflammatory markers. Computed tomography of the right thigh, abdomen and pelvis showed an abscess formation in the adductor muscles draining from the abscess that completely occupied the right retroperitoneum up to the diaphragm, dissecting downward through the inguinal canal. Appendix was enlarged with an appendicolith. Emergent exploratory laparotomy revealed a perforated appendix with psoas abscess. Pathohistological diagnosis revealed adenocarcinoma of the appendix. Thigh abscess is an uncommon condition with insidious clinical presentation. Therefore, early recognition and setting of the correct diagnosis enables adequate treatment avoiding additional complications and in some cases potential life-threatening conditions. When upper leg abscess is suspected or proven abdominal examination is mandatory.

Keywords: appendiceal cancer; appendicitis, perforated; psoas abscess; thigh;

## **INTRODUCTION**

Painful upper leg symptoms and signs are commonly associated with musculoskeletal disorders. Still, abdominal and pelvic conditions can cause thigh symptoms. Infection or a space occupying process of abdominal and pelvic organs can spread to the anatomically closely related psoas muscle and penetrate into the thigh compartments.

Psoas abscess is a rare and usually caused by a direct extension from adjacent structures or hematogeneous spread of infection from an occult or known source. If abdominal or pelvic pathology is the cause clinical presentation usually includes abdominal and pelvic symptoms. Nevertheless, infrequent cases can present with isolated thigh or gluteal symptoms as pain, swelling, skin erythema and impairment of function [1].

Appendicitis, colonic diverticulitis, inflammatory bowel disease, and colorectal carcinoma are prone to perforation with possibility of psoas or thigh abscess formation [2,3,4,5,6]. Neoplasms of the appendix are very rare and count for 0,5% of all the gastrointestinal neoplasms [7].

We report a rare case of thigh abscess as extension of psoas caused by perforation of appendiceal adenocarcinoma.

## CASE REPORT

A 65 year-old female was admitted to the Emergency Department (ED) complaining about painful, swollen, red right thigh and the mild pain in the right abdomen without nausea, vomiting or diarrhoea during one week. She had no recent trauma, bite, stab or previous fracture. Medical history revealed no chronic diseases or concomitant therapy. Seven days before because of fever (up to 37.8C) and light suprapubic discomfort her general practitioner prescribed amoxicillin suspecting urinary tract infection. Condition got worse with inability to walk due to severe pain in the right leg. Then she came to the ED: febrile (37.5°C) with stable vital signs. Physical examination showed an increased diameter of the right thigh (61 cm) compared to the left (51 cm). Erythema of the anterior and medial part of the right thigh was noticed with a palpable, extremely painful mass without signs of fluctuation. There was no inguinal lymphadenopathy. Peripheral pulses were palpable. There were no motor or sensory deficits, but active and passive movement of the right hip was impossible due to extreme pain. «Psoas sign» was positive on the right side. The rest of the physical examination was normal.

Color Doppler ultrasound excluded deep venous thrombosis. Because of elevated inflammatory parameters (leukocytes  $26,8 \times 10^9/L$ ; C-reactive protein 211,8 mg/L) the chest and right thigh X – ray and urinalysis were unremarkable. Ultrasound demonstrated inhomogeneous expansive mass 10 cm in diameter in continuity with the adductor muscles. Computed tomography (CT) showed an inhomogeneous collection in the adductor muscles spreading from the pelvis (Figure 1). CT of the abdomen and pelvis revealed abscess involving the entire right retroperitoneum, extending from the right diaphragm, along the right psoas muscle, and dissecting downward through the right inguinal canal into the right thigh with abscess formation between the adductor group of muscles. Appendix was enlarged with an intraluminally appendicolith (Figure 2). Working diagnosis was perforated appendicitis with psoas abscess with extension to the thigh.

Exploratory laparotomy revealed a perforated appendix with the tip firmly attached to the retroperitoneum. Periappendicular abscess extended through *lacuna vasorum* and *lacuna musculorum* into the right thigh. Classic appendectomy was performed. Anterior and medial muscle compartments of the right thigh were opened and large purulent collections evacuated. Incision of the retroperitoneum was done along the psoas muscle up to the confluence of right renal vein to the

inferior vena cava with evacuation of all pus. The right thigh incision was left open with everyday cleansing (Figure 3). Cultures were positive to *Escherichia coli* which was treated with ertapenem (1 g/daily for seven days). Four days later residual pus collection in the upper median part of the wound and necrosis of sartorius muscles were verified on control CT scans. Evacuation of the pus and sartorius muscle neurectomy was done and inflow irrigation system was placed. Cultures were positive to coagulase-negative staphylococci and treated with kloxacillin (4 g/daily every six hours for 7 days) added to ertapenem. Further postoperative course was uneventful. Pathohistological diagnosis revealed well differentiated colonic-type adenocarcinoma of the appendix, CK20 positive (Figure 4).

Colonoscopy revealed only diverticulosis of sigmoid and descending colon and internal haemorrhoids. Carcinoembryonic antigen was normal (0,9 µg/L). The patient was discharged after 20 days with indication for positron emission tomography – computed tomography (PET/CT) within 12 weeks in order to completely evaluate the stage of malignant disease. PET/CT did not show active malignant disease. The patient was without clinical signs and symptoms. Due to the histological characteristics and perforation of the appendix the right hemicolectomy was indicated. She rejected the procedure. The follow-up CT scan in a one year period was normal without signs of the tumor recurrence.

## DISCUSSION

Psoas abscess is a rare condition usually caused by a direct extension from adjacent structures or hematogenous spread of infection from an occult or known source. Although abdominal or pelvic pathology usually presents with abdominal and pelvic symptoms, infrequent cases can present with isolated thigh or gluteal symptoms as pain, swelling, skin erythema and impairment of function [1].

Alimentary tract infections and hematogenous spread are most common with *Staphylococcus aureus* as the most usual infectious agent [2].

Psoas abscess can penetrate into the thigh mostly as a consequence of perforated appendicitis, colonic diverticulitis, inflammatory bowel disease, and perforative colorectal carcinoma [1,3,4,5,6].

Neoplasms of the appendix are very rare and count for 0,5% of all the gastrointestinal neoplasms [7].

Recent data report the age-adjusted incidence of appendiceal cancer is only 0.12/1,000,000 people per year [8]. World Health Organization divides them into two major groups: epithelial with carcinomas and carcionoids as subgroups and non-epithelial tumours. Colonic and mucinous adenocarcinomas are histological types with highest incidence [9]. Adenocarcinomas are the most common with incidence over 50% of malignant appendiceal tumors [9,10]. The preoperative detection rate of appendiceal tumors is low, ranging from 6.6 to 25%. So far, no sufficiently accurate diagnostic modalities have been developed [11]. Adenocarcinoma of the appendix is considered one of the most frequently perforating carcinoma of the entire gastrointestinal tract [12]. Nevertheless, during clinical assessment malignancy is suspected very rarely [13]. The incidence of psoas abscess due to the perforation of the appendix is unknown. Some risk factors have been identified, like diabetes, chronic renal failure, alcohol abuse, liver cirrhosis, malignant diseases and immunosuppressive therapy [14].

We described a case of psoas and thigh abscess caused by perforation of appendiceal adenocarcinoma. To the best of our knowledge this is the first published case of perforated primary adenocarcinoma of the appendix initially presented with thigh abscess. CT scan is the imaging modality of choice for defining etiology, localization and extension of psoas abscess [15]. Although CT can show a retroperitoneal abscess clearly, it is still difficult to identify a perforated appendix or small tumors of the appendix due to the severe inflammatory process made the appendix become necrotic and indistinguishable from abscess on CT scan [16]. Current treatment guidelines for appendiceal

adenocarcinoma indicate right hemicolectomy for T2 or higher stage or even T1 stage where biology is similar to that of colorectal cancer [17]. Therefore grading, invasion and tumor type in addition to tumor localization and size should be taken into consideration when deciding whether appendectomy or hemicolectomy should be performed [18,19]. In our case the right hemicolectomy would be an optimal treatment according to guidelines. However, patient refused further surgical treatment so a more frequent follow-up is mandatory. In conclusion, this case report shows that rare medical entities often present with insidious and infrequent clinical presentation misleading physicians' clinical considerations and delaying diagnosis. Early recognition and appropriate management enables adequate treatment avoiding additional complications and in some cases potential life-threatening conditions.



Conflict of Interest Statement: The authors declare they have no conflict of interest

All human and animal studies have been approved by appropriate ethics committee. All procedures followed were in accordance with the ethical standards of the responsible committee on human experimentation and with the Helsinki Declaration 1975, as revised in 2008.

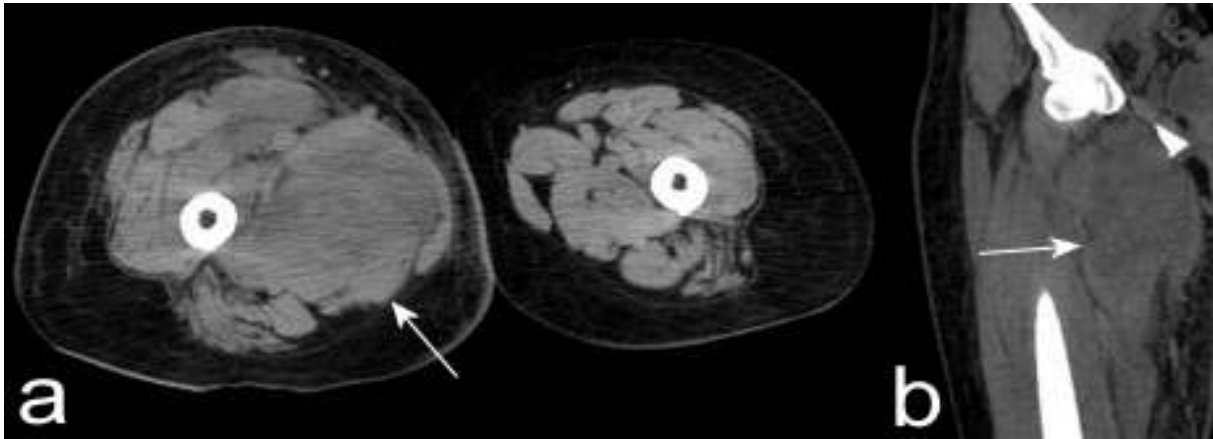
All persons gave their informed consent prior to their inclusion to the study.

## REFERENCES:

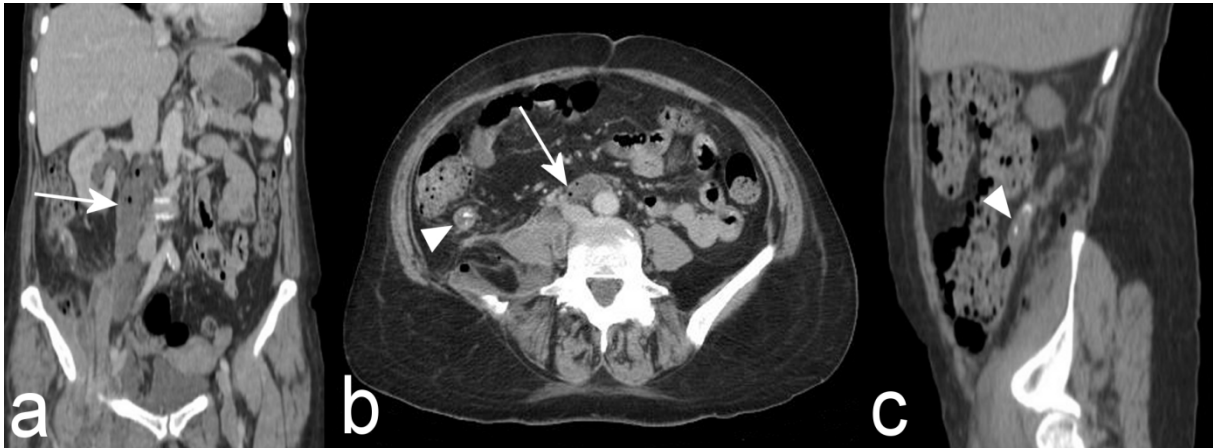
1. Kobayashi H, Sakurai Y, Shoji M, Nakamura Y, Suganuma M, Imazu H, et al. Psoas abscess and cellulitis of the right gluteal region resulting from carcinoma of the cecum. *J Gastroenterol* 2001;36(9):623-8.
2. Ricci MA, Rose FB, Meyer KK. Pyogenic psoas abscess: worldwide variations in etiology. *World J Surg* 1986;10(5):834-43.
3. Peterson CM, Allison JG, Lu CC. Psoas abscess resulting from perforating carcinoma of the sigmoid colon. Report of a case. *Dis Colon Rectum* 1983;26(6):390-2.
4. Sookraj KA, Bowne WB, Ghosh BC: Perforated appendicitis presenting as a thigh abscess. *J Am CollSurg* 2009;208:1142.
5. Mann GN, Scoggins CR, Adkins B. Perforated cecal adenocarcinoma presenting as a thigh abscess. *South Med J* 1997;90(9):949-51.
6. Hsieh CH, Wang YC, Yang HR, Chung PK, Jeng LB, Chen RJ. Extensive retroperitoneal and right thigh abscess in a patient with ruptured retrocecal appendicitis: an extremely fulminant form of a common disease. *World J Gastroenterol* 2006;12(3):496-9.
7. Chang P, Attiyeh FF. Adenocarcinoma of the appendix. *Dis Colon Rectum* 1981;24:176-80.
8. McCusker ME, Cote TR, Clegg LX, Sobin LH. Primary malignant neoplasms of the appendix: a populationbased study from the surveillance, epidemiology and end-results program, 1973-1998. *Cancer* 2002;94:3307-12.
9. World Health Organization Classification of Tumours: International Agency for research on Cancer (IARC). Pathology and Genetics of Tumours of the Digestive System. Tumours of appendix. IARC Press 2000;5:93-102.
10. Benedix F, Reimer A, Gastinger I, Mroczkowski P, Lippert H, Kube R. Primary appendiceal carcinoma – epidemiology, surgery and survival: results of a German multi-center study. *Eur J Surg Oncol.* 2010;36:763–771.
11. Oya S, Miyata K, Yuasa N, Takeuchi E, Goto Y, Miyake H et al. Early carcinoma of the appendix vermiformis. *Dig Endosc.* 2009;21:53–55.

12. Cerame MA. A 25-year review of adenocarcinoma of the appendix. A frequently perforating carcinoma. *Dis Colon Rectu* 1988;31(2):145-50.
13. Lee WS, Choi ST, Lee JN, Kim KK, Park YH, Baek JH. A retrospective clinicopathological analysis of appendiceal tumors from 3,744 appendectomies: a single-institution study. *Int J Colorectal Dis* 2011;26(5):617-21.
14. Diana M, Paroz A, Demartines N, Schäfer M. Retroperitoneal abscess with concomitant hepatic portal venous gas and rectal perforation: a rare triad of complications of acute appendicitis. A case report. *World J EmergSurg* 2010;5:3.
15. Crepps JT, Welch JP, Orlando R III. Management and outcome of retroperitoneal abscesses. *Am Surg* 1978; 205: 276-81.
16. Coursey CA, Nelson RC, Moreno RD, Dodd LG, Patel MB, Vaslef S. Carcinoid tumors of the appendix: are these tumors identifiable prospectively on preoperative CT? *Am Surg.* 2010; 76:273-5.
17. Ito H, Osteen RT, Bleday R, Zinner MJ, Ashley SW, Whang EE. Appendiceal adenocarcinoma: long-term outcomes after surgical therapy. *Dis Colon Rectum* 2004;47(4):474-80.
18. Walters KC, Paton BL, Schmelzer TS, Gersin KS, Iannitti DA, Kercher KW, Heniford BT. Treatment of appendiceal adenocarcinoma in the United States: penetration and outcomes of current guidelines. *Am Surg*2008;74(11):1066-8.
19. McGory ML, Maggard MA, Kang H et al. Malignancies of the appendix: beyond case series reports. *Dis Colon Rectum* 2005;48:2264–2271.

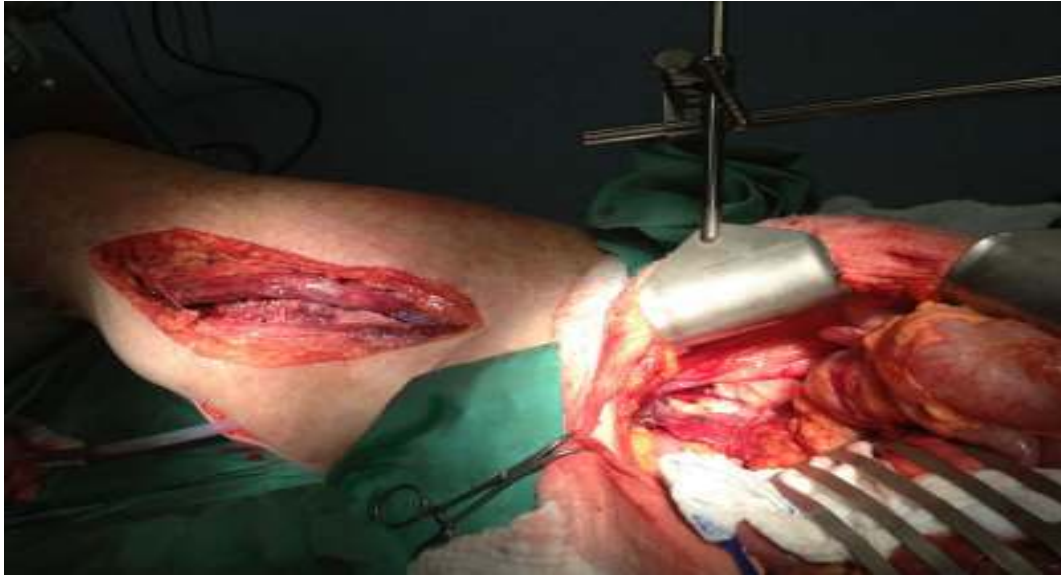**FIGURES:**



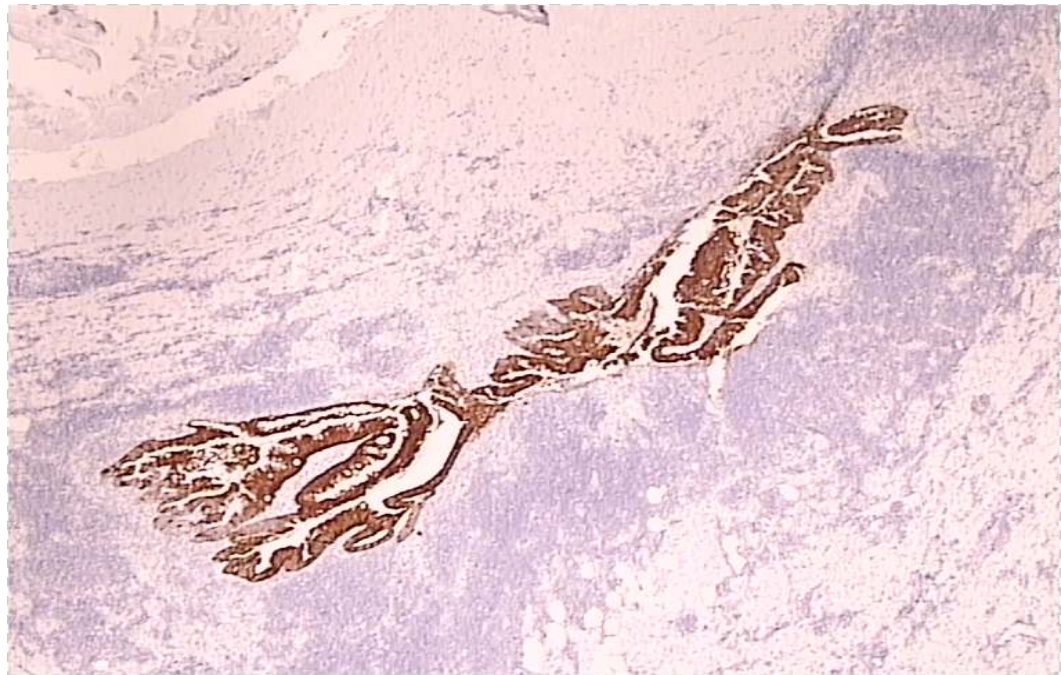
**Figure 1.**Computed tomography of the right thigh. Transverse (a) and reconstructed coronal image (b) demonstrating an abscess (arrows) in the adductor muscles spreading from the retroperitoneum through inguinal canal.



**Figure 2.**Computed tomography (reconstructed coronal (a), transverse (b) and sagittal (c)) images showing an air-containing abscess in the right retroperitoneum (arrow) and enlarged appendix with a calcified appendicolith within it (arrowhead).



**Figure 3.** Surgical drains were placed to the retroperitoneum, to the right thigh and to the abdomen. The right thigh incision was not sutured.



**Figure 4.** Pathohistological diagnosis of removed appendix revealed adenocarcinoma of the appendix immunohistochemically positive for CK20+.