



Središnja medicinska knjižnica

Adamec I., Grahovac G., Krbot Skorić M., Chudy D., Hajnšek S, Habek M. (2014) *Tongue somatosensory-evoked potentials in microvascular decompression treated trigeminal neuralgia*. Acta Neurologica Belgica, 114 (1). pp. 55-8. ISSN 0300-9009

<http://www.springer.com/journal/13760>

<http://link.springer.com/journal/13760>

<http://dx.doi.org/10.1007/s13760-013-0260-0>

<http://medlib.mef.hr/2248>

University of Zagreb Medical School Repository

<http://medlib.mef.hr/>

Tongue somatosensory evoked potentials in microvascular decompression treated trigeminal neuralgia

Ivan Adamec, MD¹, Gordan Grahovac, MD², Magdalena Krbot Skorić, MSc EE¹, Darko Chudy, MD, Sanja Hajnšek, MD, PhD^{1,3}, Mario Habek, MD, PhD^{1,3}

¹ University Hospital Center Zagreb, Department of Neurology, Referral Center for Demyelinating Diseases of the Central Nervous System, Zagreb, Croatia

² University Hospital Dubrava, Department of Neurosurgery, Zagreb, Croatia

³ School of Medicine, University of Zagreb, Zagreb, Croatia

Corresponding author:

Mario Habek, MD, PhD

University Department of Neurology

Zagreb School of Medicine and University Hospital Center

Kišpatićeva 12

HR-10000 Zagreb

Croatia

Phone: +38598883323; Fax: +38512376033; e-mail: mhabek@mef.hr

Word count: 1495

Number of references: 14

Number of figures: 2

Authors' contributions

Study concept and design: Grahovac and Habek. Acquisition of data: Adamec, Grahovac, Krbot Skorić, Chudy, Hajnšek, Habek. Analysis and interpretation of data: Adamec, Grahovac, Krbot Skorić, Chudy, Hajnšek, Habek. Drafting of the manuscript: Adamec. Critical revision of the manuscript for important intellectual content: Adamec, Grahovac, Krbot Skorić, Chudy, Hajnšek, Habek. Administrative, technical, and material support: Adamec, Grahovac, Krbot Skorić, Chudy, Hajnšek, Habek.

Conflict of interest statement: There is no conflict of interest.

Source of funding: None other than the authors own institution.

Abstract

Somatosensory evoked potentials of the tongue (tSSEP) provide useful information about trigeminal afferent pathway. The aim of this study was to evaluate tSSEP in trigeminal neuralgia treatment with microvascular decompression. Two patients with trigeminal neuralgia refractory to conservative treatment underwent microvascular decompression of the trigeminal nerve. tSSEP was performed a month prior to surgery and in the month after the surgery in both patients. Pain frequency and tSSEP were analyzed before and after surgery. In both patients a complete resolution of pain occurred. In patient 1, tSSEP latencies became shorter than before surgery and wave N1 appeared. The intensity of stimulation necessary to reach the threshold was 4 mA before the surgery and 1 mA after the surgery. A complete recovery of tSSEP after the operation was achieved in patient 2. The results of present study demonstrate potential value of tSSEP in pre-surgery evaluation and post-surgery follow-up of TN patients.

Key words: Trigeminal neuralgia, microvascular decompression, somatosensory evoked potentials of the tongue

Introduction

Trigeminal neuralgia (TN) is defined as sudden, brief, severe and recurrent episodes of pain in the distribution of one or more branches of the trigeminal nerve.¹ The classical form of TN is comprised of idiopathic cases and those caused by vascular compression of the trigeminal nerve. The proposed pathophysiological mechanism of TN is abnormal sensory impulse production in the compressed nerve and ephaptic transmission of those impulses to pain-related pathways.² The first line of therapy is sodium channel blockers, carbamazepine and oxcarbazepine.³ Evidence of efficacy of other drug classes is less well established. If the pain doesn't respond to pharmacotherapy, microvascular decompression (MVD) is the most efficient surgical technique for providing pain relief.³ However, proof of its outcome is based on patient reports and questionnaires.^{4,5} Although patients' satisfaction is arguably the most important outcome to be considered when treating pain syndromes, neurophysiological data provides us with objective evidence on nerve function recovery. We report on two patients assessed by somatosensory evoked potentials of the tongue (tSSEP) before and after MVD.

Patients and methods

Patients

Patient 1: A 58-year-old male experienced lancinating pain in the first and second division of his right trigeminal nerve for eight years. The pain was

intermittent, lasting in seconds, and pain free periods were measured in minutes.

The pain intensity (visual-analogue scale 0-7) was 7. Washing his face, talking, eating, tooth brushing and standing in the wind provoked the pain.

Pharmacotherapy was unsuccessful with trials of carbamazepine (up to 1600 mg) and pregabalin (up to 300 mg). Neurological examination revealed hyperesthesia of the right side of his face. Brain MRI demonstrated a possible vascular contact with the right trigeminal nerve in its distal part.

Patient 2: A 45-year-old male experienced sudden and brief episodes of pain in the second division of his right trigeminal nerve for 14 months prior. The pain was intermittent, lasting 2-3 minutes, and pain free periods were lasting 1-2 hours. The pain intensity (visual-analogue scale 0-7) was 7. Pain-provoking factors were touch, cold, talking, laughing, eating and tooth brushing. At the time of examination he was using carbamazepine (800 mg) with little pain relief. Hyperesthesia of the right side of his face was noted in his neurological examination. MRI of the brain demonstrated vascular compression of the right trigeminal nerve at the root entry zone.

Methods

Surgery: Microvascular decompression (MVD) of the trigeminal nerve was performed in both patients. With the patient in a supine position, a small elliptical retrosigmoid craniectomy was performed to approach the cerebellopontine angle and the trigeminal nerve.

tSSEP: tSSEP was performed a month prior to surgery and in the month after the surgery in both patients. The details of the test were described previously and are summarized here.⁶ Participants sat in a comfortable chair. Modified electroencephalogram electrodes were used for stimulation and they were located on the lateral side of the first two-thirds of the tongue. The participants had lightly opened mouth and the tongue with stimulation electrodes was held relaxed inside the mouth. Each side of the tongue (left and right) was stimulated twice with 300 trials in order to confirm the repeatability of the obtained cortical response. The stimulation was produced with constant current stimulator (Twister, Germany). The frequency of the stimulation was 3 Hz and the duration of each stimulus was 0.2 milliseconds. The polarity of the stimulation was alternating in order to avoid large baseline shifts.

At the beginning of each set of trials, the perceptive threshold for each participant was assessed. The intensity of stimulation during each set of trials was set at 3 times the perceptive threshold. It varied from the 4.5 to 10 mA. The cortical response was recorded from 4 surface disk electrodes situated at the surface of the scalp. Active electrodes were situated in the contralateral side of the scalp, according to the International 10/20 system, at the middle position between C3 and T3 for the stimulation of the right side of the tongue—C5 electrode—and at the middle position between C4 and T4 for the stimulation of the left side of the tongue—C6 electrode. Both electrodes were referred to the frontal electrode, Fz. Electrode situated at the vertex, Cz, was used as the ground electrode. Responses obtained with the electrical stimulation of the tongue were recorded with a Brain Products Vision Recorder (Germany) and the analysis of the recorded data AQ4 was performed using a Brain Products Vision

Analyzer AQ5 (Germany). Signals were filtered with bandpass filter from 0.1 to 1000 Hz. Sampling rate was 5000 Hz. For the purpose of the analysis signals were divided into segments of 70 milliseconds duration (20 milliseconds before the stimulus and 50 milliseconds after the stimulus) and averaged for each set of 300 trials. The grand average was computed from 2 averaged sets and used for analysis. The obtained responses, on the healthy side, consisted of 3 main components (N1, P1, and N2).

The primary pathogenic process that causes TN is microvascular compression, which demyelinate sensory axons in the trigeminal root.⁷ We chose tSSEP because we have the most experience with this method, and from the pathophysiological point of view, we do not expect that the site of stimulation (first, second or third branch of the trigeminal nerve) would change the results significantly.

Results

In the first patient, after careful exploration we have not found offending vessel only thickened arachnoid was evident. Trigeminal nerve was carefully released from arachnoid. The patient was pain free in the follow-up period of two months. The results of tSSEP of patient 1 are shown in figure 1 (Fig. 1). Latencies after MVD became shorter than before surgery and wave N1 appeared (Fig. 1b). The intensity of stimulation necessary to reach the threshold was 4 mA before the surgery and 1 mA after the surgery.

In the second patient, after careful exploration of the trigeminal root entry zone, the three offending vessels were identified and moved away. Teflon was used to keep the vessels in its new position far from the nerve. The patient was pain free

in the follow-up period of two months. A complete recovery of tSSEP after the operation was achieved, as shown on figure 2 (Fig. 2).

Discussion

The results of present study demonstrate value of tSSEP in evaluation of trigeminal conduction recovery after MVD. To the best of our knowledge, this is the first report on implementation of tSSEP in pre and post-surgery evaluation of TN. Altenmuller et al. have shown that peripheral lesions of the trigeminal nerve cause prolonged latencies or conduction block on somatosensory evoked potentials of the tongue.⁸ Other reports described impaired trigeminal nociceptive processing based on nociceptive and pain-related evoked potentials in TN.⁹ There have also been studies performed on application of neurophysiological monitoring of the trigeminal nerve during surgery such as usage of short latency trigeminal evoked potentials in monitoring trigeminal nerve integrity and infraorbital nerve stimulation.^{10,11} Nevertheless, there is still no widely accepted laboratory method for confirming the diagnosis of TN. Different trigeminal evoked potentials showed significantly increased latencies and statistically significant threshold elevations on the affected side.¹² However, normal trigeminal evoked potentials can be found even in the presence of a sensory deficit, emphasizing the problem with sensory examination in TN (especially hyperesthesia), which is very subjective.¹³ Considering this; tSSEP could represent a fast and safe way of determining trigeminal afferent function in a laboratory setting.

As far as treatment is concerned, MVD is considered the surgical procedure with the highest efficacy for pain relief in TN with a long-term success.^{3,5} This has

been substantiated by patient reported appraisals.⁴ The aim of our study was to determine whether we could objectify, firstly, the dysfunction of the trigeminal nerve in TN and, secondly, the effect of MVD on trigeminal nerve conduction. Although we have a sample size of only two patients the results clearly show impairment of trigeminal conduction and its recovery after surgery (Fig. 1 and 2). The less pronounced recovery of tSSEP in patient 1, we believe, is a result of longer duration of symptoms and a only a slight neurovascular conflict found during surgery, as these are factors known to affect outcome of MVD.¹⁴ To better understand the mechanism of recovery after MVD we have to look into the pathophysiology of TN. According to Love and Coakham, clinical and electrophysiological recovery after MVD result from two distinct mechanisms.¹ Clinical recovery is the result of termination of ephaptic transmission of abnormally produced sensory impulses to pain related pathways.¹ On the other hand, decompression of large myelinated fibers leads to rapid recovery of conduction latencies.¹ Surgical success in both of our patients was evident clinically from cessation of pain in their immediate post-surgical recovery period and was corroborated electrophysiologically by a fall in conduction latencies on post-surgery tSSEP.

Based on the present results we can conclude that tSSEP provides an interesting method in pre-surgery evaluation and post-surgery follow-up of TN patients.

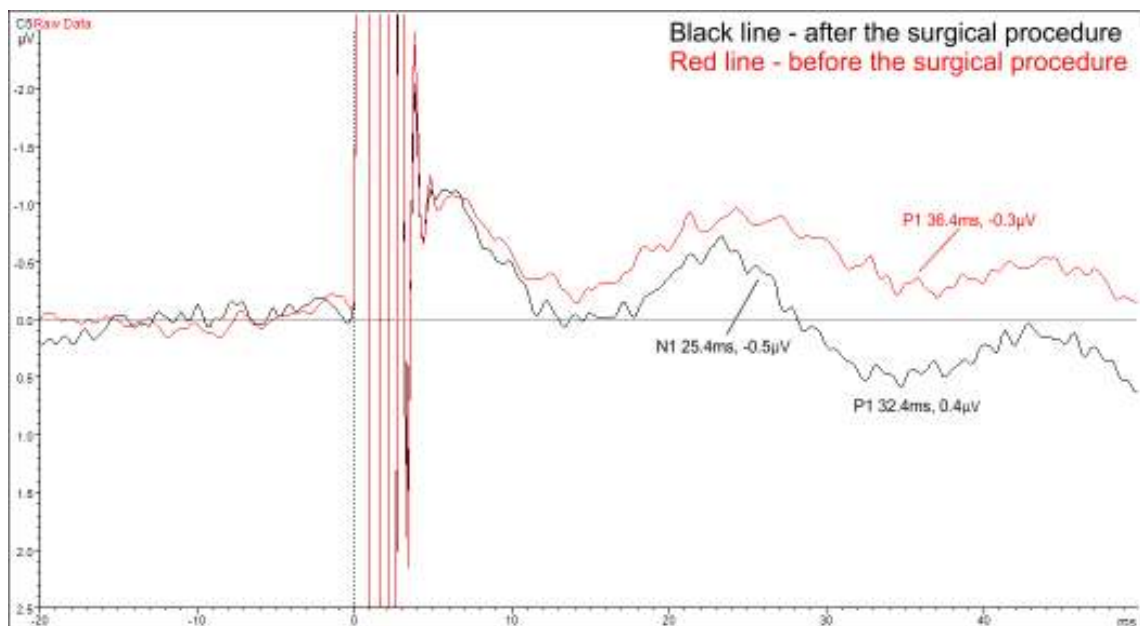
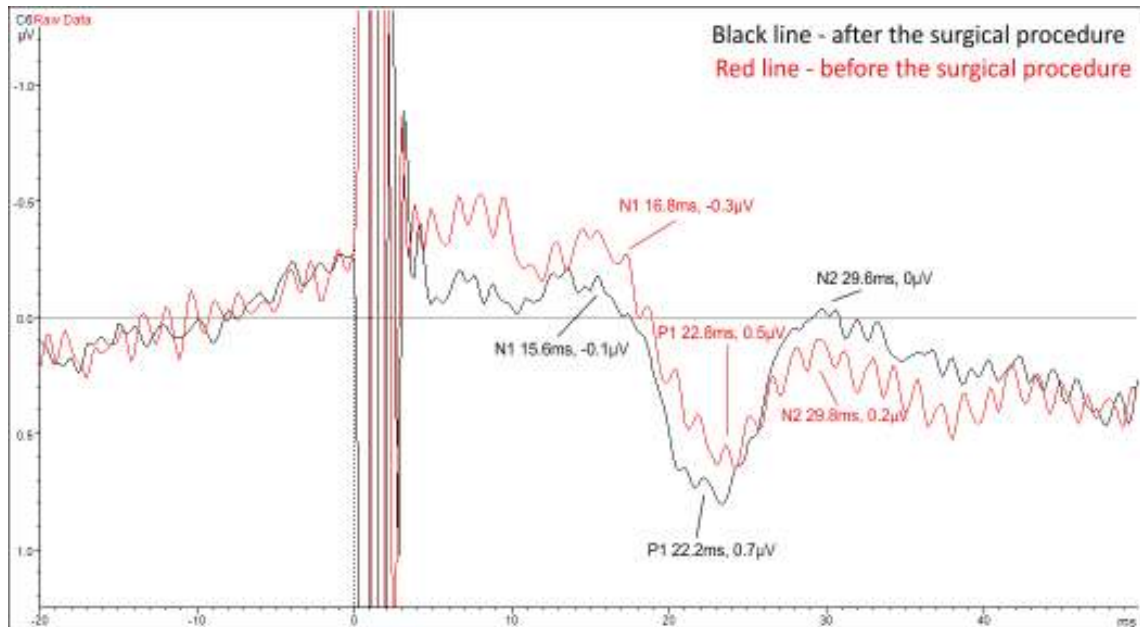
References:

1. Merskey H, Bogduk N. (1994) Classification of chronic pain. Descriptions of chronic pain syndromes and definitions of pain terms, IASP Press, Seattle, pp. 59–71.
2. Love S, Coakham HB. (2001) Trigeminal neuralgia: pathology and pathogenesis. *Brain* 124: 2347-2360.
3. Cruccu G, Gronseth G, Alksne J et al; American Academy of Neurology Society; European Federation of Neurological Society. (2008) AAN-EFNS guidelines on trigeminal neuralgia management. *Eur J Neurol* 15:1013-28.
4. Zakrzewska JM, Lopez BC, Kim SE et al. (2005) Patient reports of satisfaction after microvascular decompression and partial sensory rhizotomy for trigeminal neuralgia. *Neurosurgery* 56: 1304–1311.
5. Barker FG, Jannetta PJ, Bissonette DJ et al. (1996) The long term outcome of microvascular decompression for trigeminal neuralgia. *N Engl J Med* 334: 1077–1083.
6. Gabelic T, Krbot-Skoric M, Adamec I, Mayer D, Habek M. (2012) Tongue Somatosensory-Evoked Potentials: Evaluation of the Afferent Trigeminal Pathway in Patients With Early Multiple Sclerosis. *Clin EEG Neurosci*. doi: 10.1177/1550059412467447
7. Devor M, Amir R, Rappaport ZH. (2002) Pathophysiology of trigeminal neuralgia: the ignition hypothesis. *Clin J Pain* 18:4-13.
8. Altenmuller E, Cornelius CP, Buettner UW. (1990) Somatosensory evoked potentials following tongue stimulation in normal subjects and patients with lesions of the afferent trigeminal system. *Electroencephalogr Clin Neurophysiol* 77:403-415.

9. Obermann M, Yoon MS, Ese D, Maschke M, Kaube H, Diener HC, Katsarava Z. (2007) Impaired trigeminal nociceptive processing in patients with trigeminal neuralgia. *Neurology* 69:835-41.
10. Stechison MT. (1993) The trigeminal evoked potential: Part II. Intraoperative recording of short-latency responses. *Neurosurgery* 33:639-43; discussion 643-4.
11. Leandri M, Eldridge P, Miles J. (1998) Recovery of nerve conduction following microvascular decompression for trigeminal neuralgia. *Neurology* 51:1641-6.
12. Bennett MH, Jannetta PJ. (1983) Evoked potentials in trigeminal neuralgia. *Neurosurgery* 13:242-7.
13. Mursch K, Schäfer M, Steinhoff BJ, Behnke-Mursch J. (2002) Trigeminal evoked potentials and sensory deficits in atypical facial pain--a comparison with results in trigeminal neuralgia. *Funct Neurol* 17:133-6.
14. Li ST, Wang X, Pan Q et al. (2005) Studies on the operative outcomes and mechanisms of microvascular decompression in treating typical and atypical trigeminal neuralgia. *Clin J Pain* 21:311-6.

Figures

Figure 1. Patient 1. a) left (unaffected) side before and after surgery. b and c) right (affected) side before and after surgery.



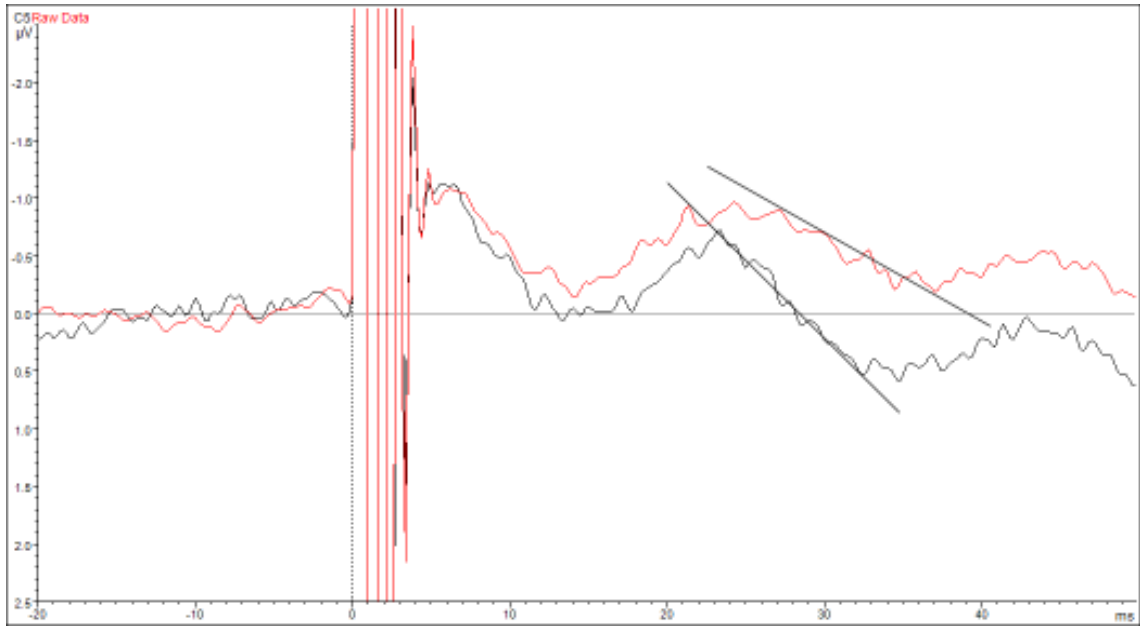


Figure 2. Patient 2. a) left (unaffected) side before and after surgery. b) right (affected) side before and after surgery.

