



Središnja medicinska knjižnica

Augustin G., Majerović M., Luetić T. (2013) *Uterine perforation as a complication of surgical abortion causing small bowel obstruction: a review*. Archives of Gynecology and Obstetrics, 288 (2). pp. 311-23. ISSN 0932-0067

<http://www.springer.com/journal/404>

<http://www.springerlink.com/content/0932-0067>

<http://dx.doi.org/10.1007/s00404-013-2749-4>

<http://medlib.mef.hr/2027>

University of Zagreb Medical School Repository

<http://medlib.mef.hr/>

Title: Uterine perforation as a complication of surgical abortion causing small bowel obstruction: A review

Short title: Uterine perforation and small bowel obstruction

Goran Augustin, Mate Majerovic, Tomislav Luetic

Department of Surgery, University Hospital Center Zagreb, Zagreb, Croatia

Goran Augustin, MD, PhD (*Corresponding author*)
Department of Surgery, University Hospital Center Zagreb
Kišpatićeva 12
10000 Zagreb, Croatia
E-mail: augustin.goran@gmail.com

Mate Majerović, MD, PhD, Prof
Department of Surgery, University Hospital Center Zagreb
Kišpatićeva 12
10000 Zagreb, Croatia
E-mail: mate.majerovic@gmail.com

Tomislav Luetić, MD, PhD, Ass Prof
Department of Surgery, University Hospital Center Zagreb
Kišpatićeva 12
10000 Zagreb, Croatia
E-mail: tluetic@mef.hr

Title: Uterine perforation as a complication of surgical abortion causing small bowel obstruction: A review

Short title: Uterine perforation and small bowel obstruction

Synopsis: Uterine perforation as a complication of surgical abortion causing small bowel obstruction is rare but should be included in the differential diagnosis of obstruction presenting hours to months after transvaginal uterine manipulation

REVIEW ARTICLE

Abstract

Objective Small bowel obstruction after unrecognized or conservatively treated uterine perforation is extremely rare. It is surgical emergency and the delay in diagnosis and treatment has deleterious consequences for the mother. The purpose of this study is to critically review the available literature and ascertain the level of evidence for the mechanisms, diagnosis and management of small bowel obstruction after uterine perforation due to surgical abortion.

Methods Systematic literature search was conducted in Pubmed from 1946 to 2012 and Pubmedcentral from 1900-2012 including all available English and French language fulltext articles. Three evaluators reviewed and selected all available case reports and case series. Search terms included: small bowel obstruction, bowel obstruction, bowel incarceration, bowel entrapment, vaginal evisceration, uterine perforation, uterine rupture, abortion. The exclusion criteria were: 1) complex injuries where small bowel incarceration was present but with bleeding and/or bowel perforation as the leading symptomatology; 2) articles only

numbering the patients without details on the topic. Analyses of incidence, risk factors, mechanisms of the disease, time of clinical presentation, diagnostic modalities, treatment and maternal outcome were included.

Results Of 73 articles screened 30 cases of small bowel obstruction were included in the review forming incidence, risk factors, and mechanisms of the disease, diagnosis, therapy and maternal outcome.

Conclusions A systematic review defined four mechanisms of small bowel obstruction after transvaginal instrumental uterine perforation with significant variations in clinical presentation and time of presentation. Duration of symptoms depend on the mechanism of small bowel obstruction. Vaginal evisceration is surgical emergency and treatment is mandatory without diagnostic workup. Survival rate during last century is 93%. Multicentric trials and publication of all such cases are needed to determine algorithms for diagnosis and management of small bowel obstruction caused by instrumental uterine perforation.

Keywords Small bowel obstruction, Uterine perforation, Abortion, Mechanism

Introduction

Let alone the fact that abortion is an extremely sensitive topic everywhere, it is perhaps unreasonable to expect reliable data about abortion practices especially in Africa or India where even vital registration - the recording of births, deaths, and marriages - is far from complete and accurate [1]. Most illegal abortions are conducted in the rural areas of developing nations without adequate facilities, and by persons with no knowledge of anatomy who operate with non-sterile instruments with increased percentage of mortality and morbidity [2-6]. As per the World Health Organization (WHO) estimates for the year 2000, about 19 million unsafe abortions occurred worldwide, resulting in the deaths of about 70,000 women [7]. One extremely rare but important complication is small bowel obstruction after surgical abortion due to uterine wall perforation. Small bowel is most commonly injured with uterine perforation because of its central pelvic location, length and mobility [3].

As yet, there have been no review articles or meta-analyses of observational studies on the subject. Therefore, in the present study, we aimed to investigate incidence, risk factors, mechanisms of small bowel obstruction, clinical presentation, diagnosis, treatment and maternal outcome *via* MOOSE criteria for the observational studies.

Methods

Study selection

We conducted a systematic literature search of Pubmed from 1946 to 2012 and Pubmedcentral from 1900-2012 including all available English and French language fulltext articles. We identified case reports dealing with small bowel obstruction after surgical abortion. The search terms were: 'small bowel obstruction', 'bowel obstruction', 'bowel incarceration', 'bowel entrapment', 'vaginal evisceration', 'uterine perforation', 'uterine rupture',

'abortion'. All the searches were restricted to human studies. All the potentially relevant articles were independently reviewed by 2 investigators (Augustin G and Luetic T).

Disagreements between evaluators were resolved by discussion or consultation with a third author (Majerovic M).

The exclusion criteria were: (1) complex injuries when small bowel incarceration was present but with bleeding and/or bowel perforation as the leading symptomatology, (2) uterine perforation after dilation and curettage after labor for any cause and (3) articles on the topic only numbering the patients without important data.

One inaccuracy in included articles is that some important procedures are not described precisely such as abortion. The terms used are 'abortion', 'surgical abortion' or 'instrumental abortion' without precisely defining the procedure itself.

Data synthesis

The study aimed to investigate incidence, risk factors, mechanisms of small bowel obstruction, clinical presentation, diagnosis, treatment and maternal outcome. Most of the outcome measures were unsuitable for meta-analysis, and we calculated crude estimates. Several interrelations were analyzed: (1) Possible influence of pregnancy duration and other possible risk factors on incidence, (2) mechanism of small bowel obstruction on duration of symptoms, (3) duration of symptoms and vital signs on outcome, (4) extension of resection on outcome.

Statistical analysis

Adequate statistical analysis was not possible due to the lack of one or more of analyzed data in almost every study included. Only possible relations in percentages could be calculated.

Results

Identification of relevant studies

Table 1 show studies with relevant data. Of the 73 articles screened we identified 30 cases having the majority of data important for this study. The only one important study by Ntia et al. was excluded having the largest number of patients (9 patients) but only the abstract was available and presenting with only one of four mechanisms of small bowel obstruction (see *Mechanisms of small bowel obstruction*) [8]. The results of this study were used in the discussion for the comparison with some of our results.

Characteristics of the studies included in the analyses

There were 30 cases included. The problem with data interpretation is that in this extremely small group of studies (patients), detailed description is lacking. In some case reports some important data are missing and in others with case series, cumulative data are presented and it is impossible to further analyze the subgroups defined in our study. The percentages were calculated not from the entire group of 30 cases but from the number of available data for the specific factor analyzed. The Meta-analysis Of Observational Studies in Epidemiology (MOOSE) guidelines were consulted throughout the conduct of the study and MOOSE checklist presented (Table 2).

Discussion

Incidence and trimester distribution

Worldwide, there are 30-50 million induced abortions [7, 9]. First trimester surgical abortion is one of the most frequently performed procedures in the United States: 853,485 procedures were performed in 2001 [10]. In a large study evaluating morbidity, Hakim-Elahi et al. reported incidence of minor complications after first trimester surgical abortion of 0.846%,

including mild infection, resuctioning on the day of procedure, or subsequent resuction, cervical stenosis, cervical tear, underestimation of gestational age, and convulsive seizure after local anesthesia [11]. Major complications requiring hospitalization have ten times less incidence (0.071%) and include incomplete abortion, sepsis, uterine perforation, vaginal bleeding, inability to complete abortion, and combined (heterotopic) pregnancy. Uterine perforation during abortion is rare, with incidence of 0.05 - 0.4% [12-17] but up to 3.6% in undeveloped countries [18].

Small bowel obstruction caused by uterine perforation due to surgical abortion, as one of major complications, is extremely rare. Our study included 30 patients after surgical abortion in the period 1907-2012 due to adequacy of the data. There are less than 50 patients in the literature and the remainder was excluded due to only numbering or clustering in the articles without important data for this study. First described in 1864, the total number of case reports of all cause vaginal evisceration (as one mechanism of small bowel obstruction after surgical abortion), is less than 100 cases [19]. Extremely rare incidence of small bowel obstruction after uterine perforation due to surgical abortion is due to:

- (1) rare occurrence of instrumental uterine perforation
- (2) spontaneous healing of most (recognized and unrecognized) uterine perforations without further complications [16, 20]
- (3) immediate laparotomy/laparoscopy in 47-84% of cases with recognized complicated uterine perforation [14, 17]
- (4) unknown number of cases not published in the medical literature
- (5) prehospital mortality, especially in undeveloped countries [21]

Therefore real incidence is unknown, higher than published, but still, fortunately, extremely low. First known published case of vaginal evisceration as one form of small bowel obstruction due to uterine perforation after instrumental abortion is from 1864 with several

cases published between 1907 and 1911 [22-26] and then from 1923-1924 [27, 28]. New cases are then published in the middle of the 20th century [29, 30] and then in average of 2 cases in every decade up to 2005 when every year at least one case was published (Table 1).

Approximately 71% (15/21) were during the first trimester and remaining 27% (6/22) during the second trimester. The distribution of this complication through the trimesters is contrary to the fact that second trimester abortion has a higher rate of all complications than abortions performed in the first trimester [13, 15, 31]. This is due to: (1) higher incidence of (legal or illegal) surgical abortions during the first trimester and (2) thickening of the uterus as pregnancy advances lowering the possibility of instrumental perforation.

Risk factors

In an attempt to identify factors potentially leading to uterine perforation, several authors determined that the level of training was the strongest statistically significant risk factor for perforation [8, 32]. Other factors were advanced maternal age, greater parity, retroverted uterus, history of prior abortion or cesarean section, history of previous cone biopsy, failure to use ultrasound, and underestimation of the duration of pregnancy [13-15, 33]. In a study by Amarin and Badria uterine perforations were mostly located at the uterine fundus, presumably caused by the introduction of cervical dilators [34]. Hence, difficulty during cervical dilatation also has been associated with a higher perforation rate, and some authors recommend prostaglandin use to aid in dilatation of the cervix [13, 15]. Additionally, prostaglandins have the benefit of contracting the uterus, which may help decrease the perforation rate [14]. In our study 63% (12/19) had perforation in the fundus confirming the results of previous studies also in this subpopulation of complicated uterine perforations. Currently there are no known risk factors for small bowel obstruction after uterine

perforation. Unfortunately, there are insufficient data for the conclusions but three factors could influence on increase of the incidence (Table 1):

(1) *failed medical abortion* [33, 35]

(2) *curettage for retained parts of the placenta after previous pregnancy* [26, 36]

(3) *diameter of uterine perforation*

(4) *multiple pregnancies*

Ad 2. It should be added that Chang et al. other possible explanation, although farfetched, could be that it was a cesarean scar pregnancy (one of the rarest form of ectopic pregnancy) where the uterine wall is the weakest and more likely to perforate after endometrial curettage [33].

Ad 3. All cases with described size of uterine perforation had diameter larger than 1 cm and 70% (7 out of 10) had perforations larger than 2 cm (Table 1). It could be hypothesized that the larger the size of perforation the easier for the bowel to incarcerate through the uterine wall or to eviscerate. From these small numbers it cannot be concluded does the size of the perforation raise the possibility of formation of adhesions with small bowel.

Ad 4. Sixteen patients had documented previous pregnancies. Only one patient was nulliparous, three (19%) had one pregnancy, four (25%) had two pregnancies and eight (50%) had three or more pregnancies. Authors did not analyze correlation with previous pregnancies due to the lack of data and also with abortions because it is known that abortions are not always recorded in the medical documentation.

We conclude that we should be cautious with these proposed risk factors due to the small number of patients and these observations should be scientifically tested.

Mechanisms of small bowel obstruction

There are four documented mechanisms of small bowel obstruction after uterine perforation due to surgical abortion. Most common is due to small bowel prolapse (Fig 1) through uterine perforation due to inadvertent aspiration, spontaneous protrusion through large perforation or by inadvertent pulling of small bowel. The incidence of small bowel incarcerated in the uterine wall is 23%. The most extensive type is when the small bowel loops are pulled out of vaginal introitus (Fig 2) present in additional 60% of patients (Table 1). This mechanism is responsible for the majority of cases (83%). Vaginal evisceration of small bowel is the final pathophysiologic event of the several causes which can sometimes coexist [35]: 1) radiation due to gynecologic cancer, 2) gynecologic surgery, 3) enterocele, 4) coital injury/rape, 5) douching, 6) enema expulsion, 7) speculum insertion, 8) fall and 9) spontaneous (thin and stretched-out vaginal apex) therefore history taking is crucial.

Second mechanism is when uterine perforation contains incarcerated herniated omentum (Fig 3) [59], and a band attached to the omentum strangulates a segment of the extrauterine small bowel producing obstruction. It was documented in only one patient making the incidence of 3% [12]. The third mechanism is when the small bowel is entrapped in adhesions at the site of uterine perforation with incidence of 10% [37-39]. One possible confounding factor could be previous intraperitoneal surgery causing adhesions between small bowel and uterus. We did not find such cases in our study. Fourth mechanism is obstruction as Richter type of hernia when the antimesenteric wall of the intestine protrudes through a defect in the uterine wall with rare incidence of 3% (Fig 4) [36]. Our explanation for long period of symptomless Richter type small bowel obstruction follows. During the first pregnancy (2 years previously), a dilation and curettage had been performed 4 weeks after delivery, to remove the retained placenta. During instrumentation the uterine wall perforation occurred with formation of Richter type hernia but without ischemia of the small bowel wall. In the

advanced stage of second pregnancy, growing uterus made compression and occlusion of the small bowel that was fixed to the uterus previously as Richter type of hernia.

Clinical presentation

The uterine perforations are usually recognized at the time of the dilation and curettage. If unrecognized, majority of patients have uncomplicated course with spontaneous healing of uterine perforations (see *Incidence and trimester distribution* section). The type and time of presentation depend on two pathophysiologic processes that could coexist (iatrogenic bowel perforation is excluded):

(1) Mechanism of small bowel obstruction

(2) (Associated) bleeding

- a. From uterine wall around perforation
- b. From the mesentery detached from its bowel [40]

Ad 1. The mechanism of small bowel obstruction dictates the severity, intensity and time of presentation of obstruction. If adhesions are the cause of partial or progressive small bowel obstruction than non-specific symptoms including abdominal pain with/without distension, vomiting, (paradoxal) diarrhea or absence of flatus and/or stool is present. Fever and chills are present in the advanced stage when small bowel gangrene ensues. A serious consideration of this possibility is necessary, as the intrauterine location of strangulated bowel may mask the characteristic peritoneal signs [12]. Ischemic bowel perforation should be pathophysiologically differentiated from the direct bowel injury during instrumental uterine perforation. Such injuries develop clinical picture mostly within few hours after the procedure [41]. In our study duration of symptoms due to adhesions was from 4 days to 4 months in four patients (Table 1). These symptoms cause the delay in diagnosis because the patients with partial obstruction are commonly managed conservatively [42]. Presentation after 2 years was

due to Richter type of hernia. Presentation of Richter hernia is not predictable. It can incarcerate initially with early presentation or other pathophysiologic event should be present for initiation of obstruction. Probably it depends partly on the size of uterine perforation. Such mechanism of delayed presentation was present in one patient in our study [36]. If the incarceration of the bowel through uterine wall is present and not recognized during abortion and if complete obstruction due to bowel prolapse through the uterine wall is the cause then all patients presented from one hour to 48 hours after uterine instrumentation (Table 1). If the small bowel is prolapsed in a form of vaginal evisceration the diagnosis is evident clinically due to the vaginal small bowel prolapse.

Ad 2. Any mechanism of small bowel obstruction could be accompanied with hemorrhage either from uterine wall perforation or detached mesentery from its bowel. Clinically, hemorrhage from uterine wall perforation is evident due to transvaginal bleeding but mesenteric bleeding can present either with transvaginal or intraabdominal bleeding or both. An intraabdominal bleeding present as abdominal pain and is difficult to confirm it clinically due to abdominal pain caused by coexisting small bowel obstruction with abdominal distension. It is difficult to conclude is hemorrhage or small bowel obstruction dominant in these patients because variations in severity of developing obstruction and variations in severity of bleeding could be present. In our study 7 of 18 patients were hypotensive making it 39%.

Diagnosis

Diagnostic algorithm depends on the clinical presentation. If patient presents with vaginal evisceration with history of recent surgical abortion additional diagnostic workup is unnecessary especially when the patient lost significant amount of blood. In our study all 14

patients where detailed diagnostic algorithm was described were sent directly to operating room without any diagnostic modality performed.

When non-specific symptoms including abdominal pain with/without distension, vomiting, diarrhea, or absence of stool and/or flatus are present, plain abdominal X-ray is mandatory. In our study, 12 patients presented without vaginal small bowel prolapse. Eight patients had data about diagnostic workup and plain abdominal X-ray was performed in 7 (87.5%). Unfortunately, it is impossible to have detailed data how much time elapsed after first presentation until plain abdominal X-ray was performed because the timing is as important as the percentage of its use in this subpopulation. The diagnosis is likely when air-liquid levels of small bowel are evident on plain abdominal X-ray.

In the emergently presenting patient, ultrasound is the preferred diagnostic modality for the gynecologist, but it should be recognized that the normal appearance of the uterus after a first trimester surgical abortion can be quite variable [43-45]. Ultrasound diagnosis of uterine perforation with suspected bowel entrapment was first reported in 1983 by Dunner et al [46]. Defect in the uterine wall could be detected with the transabdominal ultrasound. Tubular-shaped irregular tissue could be seen within the endometrial cavity, with a small echogenic focus suggesting the presence of air (Fig 5). An abnormally increased amount of echogenic free fluid could be seen in the cul-de-sac [47]. In all cases without vaginal evisceration with documented diagnostic workup transabdominal ultrasound was performed (5 patients).

Transvaginal sonography can delineate free fluid in the pelvis, loops of bowel within the myometrial wall, extrauterine fetal parts or intraoperative presence of the curette within the myometrium and is used to confirm uterine perforation [48]. It can also delineate bright, serpiginous, fluid-filled tubular structures within the endometrial cavity (Fig 6). It was used in 4 of 5 aforementioned patients in our study (80%). It is not indicated if the diagnosis is clear

on transabdominal ultrasound or vice versa. Adjacent material of increased echogenicity could be suggestive of fat. Color Doppler would not show blood flow in these structures and no peristalsis would be seen in the intrauterine contents [47]. There are not data about its use in our study so further conclusions cannot be drawn.

The first reported CT diagnosis of incarcerated bowel in a uterine perforation was by Chang et al. in 2008 [33]. Evaluation with CT has an important diagnostic role in cases where ultrasound is ambiguous or if nongynecological pathology is suspected. Although the uterine wall can hinder visualization of intrauterine bowel loops, Dignac et al. emphasize that the bowel's mesentery can be well visualized on CT scan due to its fatty nature, and should be a red flag for intrauterine bowel [33] and bowel loops within the uterus can be seen (Fig 7). In our study only two patients had abdominal CT scan. There are two reasons: 1) routine CT use during last several decades and 2) defined pathology clinically, or with plain abdominal X-ray or pelvic ultrasound eliminate the need for CT diagnosis.

Finally, abdominal/pelvic MRI has been utilized to assess the endometrial cavity after a first trimester surgical abortion [44], but it is not routinely performed on an emergent basis. There is only one case showing incarceration of the greater omentum in the uterine perforation but without bowel obstruction [49]. In our study and available literature there has been no case of small bowel obstruction due to uterine perforation using MRI published.

Therapy

Uterine perforations should be divided into uncomplicated and complicated uterine perforations. Most uterine perforations recognized during abortion without complications could be managed conservatively [14, 15]. Kaali et al. managed conservatively 22 perforations after 7114 elective abortions, significant number of these perforations detected during combined laparoscopy [16]. This implies that the true perforation rate may be under-

reported and under-recognized without severe consequences to patients, suggesting that conservative management of uncomplicated uterine perforations with close observation is typically adequate [14, 50, 51].

The diagnosis or even suspicion of intrauterine bowel/bowel injury (complicated uterine perforation), however, mandates emergency laparotomy or laparoscopy. Emergency laparotomy/laparoscopy is necessary to prevent the progressive bowel distention with ensuing ischemic necrosis and/or subsequent perforation of the bowel. During laparotomy/laparoscopy the bowel should be reduced into the peritoneal cavity and evaluated for vitality. The involved herniated bowel may be strangulated, have direct bowel wall trauma, or may be devascularized by coexistent injury or incarceration of the mesentery [42]. In our study, in all cases of vaginal evisceration resection was necessary. In 14 of 18 patients the length of resected small bowel was measured. In only one patient the resected length was 30 cm and in all others the minimal resected length was 100 cm. In 56% of patients (10/18) more than 200 cm was resected. In the subgroup of patients with ileal adhesion (three patients), the resection of ischemic bowel was necessary in two patients (67%). The question is could the bowel be saved with earlier diagnosis and operation earlier in the course of the disease, but the answer cannot be made because the lack of all necessary data.

Diversion in form of a stoma was made in only one patient with complete small bowel resection. It should be performed in patients with hemorrhagic shock or in sepsis due to late presentation with gross purulent and/or fecal contamination of the peritoneal cavity. Our study with isolated small bowel obstruction shows that resection with anastomosis is preferred treatment in patients without peritonitis.

Uterine perforation/laceration should be repaired after treatment of small bowel injury. Sometimes uterine perforation should be enlarged for easier pulling of the bowel into peritoneal cavity minimizing the possibility of further bowel and mesenteric damage (two

patients) [40, 52]. Rarely, a hysterectomy is required if the uterus is necrotic or irreparable [41, 48]. Hysterectomy was performed in 4 of 7 patients from the first half of the century and none after 1966. Our conclusion is that uterine debridement with suture repair is the procedure of choice despite description of one patient without repair of uterine perforation where perforation size was 1 cm [12].

Further surgical and perioperative treatment strategy was not analyzed in our study due to the lack of data but it should be mentioned. Preoperative consultation with the patient for permanent sterilization should be done because during operation it is short additional procedure that could prevent repeating of complications of further abortions. During surgical exploration a search for mutilated fetus should be done [53] with definitive curettage if necessary. Perioperative antibiotics should be administered as in bowel obstruction in general. During follow-up, ultrasonogram of the uterus and β HCG measurement should be performed to eliminate the possibility of retained products of conception [53].

Prognosis

Worldwide, there are 30-50 million induced abortions that result in the death of 80,000 - 110,000 women of which an estimated 34,000 are in Sub-Saharan Africa [7, 9].

Appropriately timed surgical intervention in complicated uterine perforation is crucial to decrease morbidity and mortality rates. Available data in our study show the survival rate of 93% (two deaths) during whole century (1907 – 2012). One patient died due to massive small bowel necrosis where resection with high jejunostomy was made. The girl left the hospital against medical advice for social and family reasons and died [6]. Our assumption is that high jejunal stoma with high output caused dehydration and electrolyte imbalance finally causing death. Second patient had additional sigmoid colon laceration treated during initial operation with resection and anastomosis. Authors write that the patient became febrile and deteriorated

on the fourth postoperative day. Our assumption is that dehiscence of colorectal anastomosis with diffuse stercoral peritonitis and subsequent septic shock with multiorgan failure ensued [35]. The results of this study show that excellent prognosis is present throughout whole century and it is due to several reasons:

- 1) population of these patients is young, mostly without comorbidities and can compensate significant pathophysiologic stress such as small bowel obstruction and/or perforation sometimes accompanied with various degree of hemorrhage. Such conditions could be deleterious for old people especially with significant comorbidities
- 2) most patients present with evident small bowel obstruction either clinically as vaginal evisceration (60% of patients) or during first 48 hours with small bowel in uterine wall (23% of patients) mostly diagnosed fast and accurate with pelvic sonography. Small bowel obstruction in remaining patients was confirmed with plain abdominal X-ray before perforation ensued
- 3) complications of small bowel resection in young, healthy patients without advanced atherosclerosis are rare and even long segmental resections have good long term prognosis.

Conflict of interest No conflicts of interest.

References

1. Babu NP, Nidhi, Verma RK (1998) Abortion in India: what does the National Family Health Survey tell us? *J Family Welfare* 44:45-53
2. Rao B (1980) Maternal mortality in India: a review. *J Obstet Gynaecol India* 30:359
3. Imoedemhe D, Ezimokhai M, Okpere E, Aboh IFO (1984) Intestinal injuries following induced abortion. *Int J Gynecol Obstet* 22:303-306
4. Megafu U (1980) Bowel injury in septic abortion: the need for more aggressive management. *Int J Gynecol Obstet* 17:450-543
5. Chhabra R (1996) Abortion in India: an overview. *Demography India* 25:83-92
6. Jhobta RS, Attri AK, Jhobta A (2007) Bowel injury following induced abortion. *Int J Gynaecol Obstet* 96:24-27
7. Grimes DA, Benson J, Singh S, Romero M, Ganatra B, Okonofua FE, Shah IH (2006) Unsafe abortion: the preventable pandemic. *Lancet* 368:1908-1919
8. Ntia IO, Ekele BA (2000) Bowel prolapse through perforated uterus following induced abortion. *West Afr J Med* 19:209-211
9. Laguardia KD, Rotholz MV, Belfort P (1990) A 10-year review of maternal mortality in a municipal hospital in Rio de Janeiro: a cause for concern. *Obstet Gynaecol* 75:186-190
10. Strauss LT, Herndon J, Chang J, et al (2004) Abortion surveillance—United States, 2001. *Morb Mortal Wkly Rep CDC Surveill Summ* 53:1–32
11. Hakim-Elahi E, Tovell HM, Burnhill MS (1990) Complications of first-trimester abortion: a report of 170,000 cases. *Obstet Gynecol* 76:129–135
12. Leibner EC (1995) Delayed presentation of uterine perforation. *Ann Emerg Med* 26:643–646

13. Grossman D, Blanchard K, Blumenthal P (2008) Complications after second trimester surgical and medical abortion. *Reprod Health Matters* 16:173–182
14. Lindell G, Flam F (1995) Management of uterine perforations in connection with legal abortions. *Acta Obstet Gynecol Scand* 74:373–375
15. Pridmore BR, Chambers DG (1999) Uterine perforation during surgical abortion: a review of diagnosis, management and prevention. *Aust N Z J Obstet Gynaecol* 39:349–353
16. Kaali SG, Szigetvari IA, Bartfai GS (1989) The frequency and management of uterine perforations during first-trimester abortions. *Am J Obstet Gynecol* 161:406–408
17. Mittal S, Misra SL (1985) Uterine perforation following medical termination of pregnancy by vacuum aspiration. *Int J Gynaecol Obstet* 23:45-50
18. Obed SA, Wilson JB (1999) Uterine perforation from induced abortion at Korle Bu Teaching Hospital, Accra, Ghana: a five year review. *West Afr J Med* 18:286-289
19. Nasr AO, Tormey S, Aziz MA (2005) Vaginal herniation: case report and review of the literature. *Am J Obstet Gynecol* 193:95–97
20. Aktun H, Cakmak P, Moroy P, Moroy P, Minareci Y, Yalcin H, et al (2006) Surgical termination of pregnancy: evaluation of 14,903 cases. *Taiwan J Obstet Gynecol* 45:221-224
21. Oladapo OT, Coker AA (2005) Bowel prolapse and gangrene following vaginal vault perforation: an example of the menace of criminal abortion in Nigeria. *Trop Doct* 35:177–178
22. Werelius A (1907) Successful resection of twelve feet and two inches of the ilium in case of criminal abortion. *J Am Med Assoc* 48:945
23. Donaldson HJ (1908) An unusual obstetric complication causing the removal of 126 inches of small intestine. *Surg Gynecol Obstet* 6:417

24. Congdon C (1906) Abdominal section for trauma of the uterus. *Am J Obstet* 54:618
25. Nixon Davis WJ (1908) Perforation of uterus during curettage and excision of fifteen feet and a few inches of intestine, with recovery. *Illinois Med J*
26. Whitall JD (1911) Extensive removals of intestine: report of a case of recovery after resection of ten feet eight inches of the ileum. *Ann Surg* 54:669-672
27. Palmer AC (1924) A case in which over 3 ft. of small intestine were dragged out through a perforation in the uterus. *Proc R Soc Med* 17:15-18
28. Sarnoff J (1923) Extensive resection of the small intestine: Report of the recovery after resection of fifteen feet of small intestine and hysterectomy. *Ann Surg* 78:745-750
29. Wolff JR, Limarzi LR (1946) Blood disorders associated with pregnancy; the value of sternal marrow biopsy. *Am J Obstet Gynecol* 51:447-466
30. Haddad F, Haddad S (1949) *Ann Report of Orient Hospital, Beirut* 2:50
31. Diedrich J, Steinauer J (2009) Complications of surgical abortion. *Clin Obstet Gynecol* 52:205–212
32. Grimes DA, Schulz KF, Cates W (1984) Prevention of uterine perforation during curettage abortion. *J Am Med Assoc* 251:2108–2111
33. Chang HM, Shen CJ, Lin CY, Tsai EM (2008) Uterine perforation and bowel incarceration following surgical abortion during the first trimester. *Taiwan J Obstet Gynecol* 47:448–450
34. Amarin ZO, Badria LF (2005) A survey of uterine perforation following dilatation and curettage or evacuation of retained products of conception. *Arch Gynecol Obstet* 271:203–206

35. Aliyu LD, Salihu MB. Uterine perforation with associated bowel prolapse per vaginum during attempted termination of pregnancy at peripheral Hospital: A Case Report. *Nigerian J Med*
36. Seow-En I, Seow-Choen F, Tseng PT (2010) Prior uterine perforation resulting in intestinal obstruction in a subsequent pregnancy. *Tech Coloproctol* 14:369
37. Cooke WA (1956) Perforation of the uterus. *Can Med Assoc J* 93:609-611
38. Coughlin LM, Sparks DA, Chase DM, Smith J (2012) Incarcerated Small Bowel Associated with Elective Abortion Uterine Perforation. *J Emerg Med* [Epub ahead of print].
39. Nkor SK, Igberase GO, Osime OC, Faleyimu BL, Babalola R (2009) Small bowel obstruction following perforation of the uterus at induced abortion. *West Afr J Med* 28:337-339
40. Dossou FM, Hounkpè PC, Tonato Bagnan JA, Dénakpo J, Sohoun P (2012) Small bowel prolapsed through perforated uterus following illegal induced abortion. *Surgery Curr Res* 2:118
41. Coffman S (2001) Bowel injury as a complication of induced abortion: a case report and literature review. *Am Surg* 67:924–926
42. Kambiss SM, Hibbert ML, Macedonia C, Potter ME (2000) Uterine perforation resulting in bowel infarction: sharp traumatic bowel and mesenteric injury at the time of pregnancy termination. *Mil Med* 165:81-82
43. Dillon EH, Case CQ, Ramos IM, Holland CK, Taylor KJ (1993) Endovaginal US and Doppler findings after first trimester abortion. *Radiology* 186:87–91
44. Ascher SM, Scoutt LM, McCarthy SM, Lange RC, DeCherney AH (1991) Uterine changes after dilation and curettage: MR imaging findings. *Radiology* 180:433–435

45. Bar-Hava I, Aschkenazi S, Orvieto R, Perri T, Shalev J, Dicker D, et al (2001) Spectrum of normal intrauterine cavity sonographic findings after first trimester abortion. *J Ultrasound Med* 20:1277–1281
46. Dunner PS, Thomas MA, Ferreras M, Jerome M (1983) Intrauterine incarcerated bowel following uterine perforation during an abortion: a case report. *Am J Obstet Gynecol* 147:969-970
47. Shulman SG, Bell CL, Hampf FE (2006) Uterine perforation and small bowel incarceration: sonographic and surgical findings. *Emerg Radiol* 13:43-45
48. Sherer DM, Gorelick C, Gabbur N, Borowski D, Serur E, Zinn HL et al (2007) Transvaginal sonographic findings of a large intramural uterine hematoma associated with iatrogenic injury sustained at termination of pregnancy. *Ultrasound Obstet Gynecol* 30:110–113
49. Koshiha A, Koshiha H, Noguchi T, Iwasaku K, Kitawaki J (2012) Uterine perforation with omentum incarceration after dilatation and evacuation/curettage: magnetic resonance imaging findings. *Arch Gynecol Obstet* 285:887-890
50. Dignac A, Novellas S, Fournol M, Caramella T, Bafghi A, Chevallier P (2008) Incarceration of the appendix complicating a uterine perforation following surgical abortion: CT aspects. *Emerg Radiol* 15:267–269
51. Davies MF, Howat JM (1990) Intestinal obstruction secondary to uterine perforation: an unusual cause of vaginal bleeding. *Br J Clin Pract* 44:331-332
52. McArdle CR, Goldberg RP, Rachlin WS (1984) Intrauterine small bowel entrapment and obstruction complicating suction abortion. *Gastrointest Radiol* 9:239-240
53. Sherigar JM, Dalal AD, Patel JR (2005) Uterine Perforation with subtotal small bowel prolapse –A rare complication of dilatation and curettage. *Online J Health Allied Scs*

54. Shenoj PM, Smits BJ, Davidson S (1966) Massive removal of bowel during criminal abortion. *Brit Med J* 519:929–931
55. Gupta S, Chauhan H, Goel G, Mishra S (2011) An unusual complication of unsafe abortion. *J Family Community Med* 18:165-167
56. Lebeau R, Guié P, Bohoussou E, Akpa-Bédi ES, Akpa-Bédi ES, Loukou Y, et al (2012) An uncommon complication of unsafe induced abortion: Bowel prolapse through uterine perforation [Article in French]. *Gynecol Obstet Fertil* [Epub ahead of print].
57. Oludiran OO, Okonofua FE (2003) Morbidity and mortality from bowel injury secondary to induced abortion. *Afr J Reprod Health* 7:65-68
58. Aworinde O, Oyetunji I, Olufemi-Aworinde K, Adebajo A, Olusola F (2011) Total Ileal Resection with Right Hemicolectomy Following Unsafe Abortion: Unusual Ileocecal Prolapse. *J Gynecol Surg* 27:185-187
59. Sangam PS, Jayakumar NM, Yaliwal LV (2011) Uterine perforation with omental prolapse in a case of unsafe abortion. *Asian J Med Sci* 2:145-147

Figure legends

Fig. 1 Intraoperative photograph demonstrates a defect in the anterior myometrium of the uterus (UT) at the level of the left round ligament (RL), through which small bowel (SB) has become incarcerated [47]

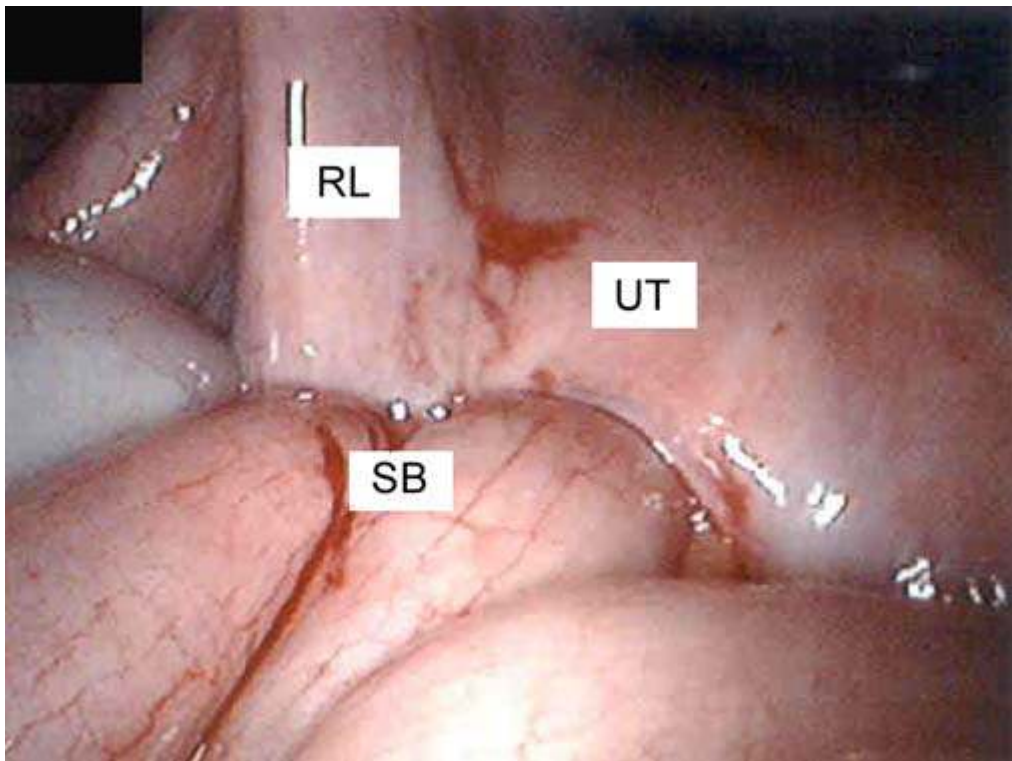


Fig. 2 Congested and edematous intestinal loops pulled out of vaginal introitus 2 hours following evacuation of the uterus done for an incomplete abortion [55]

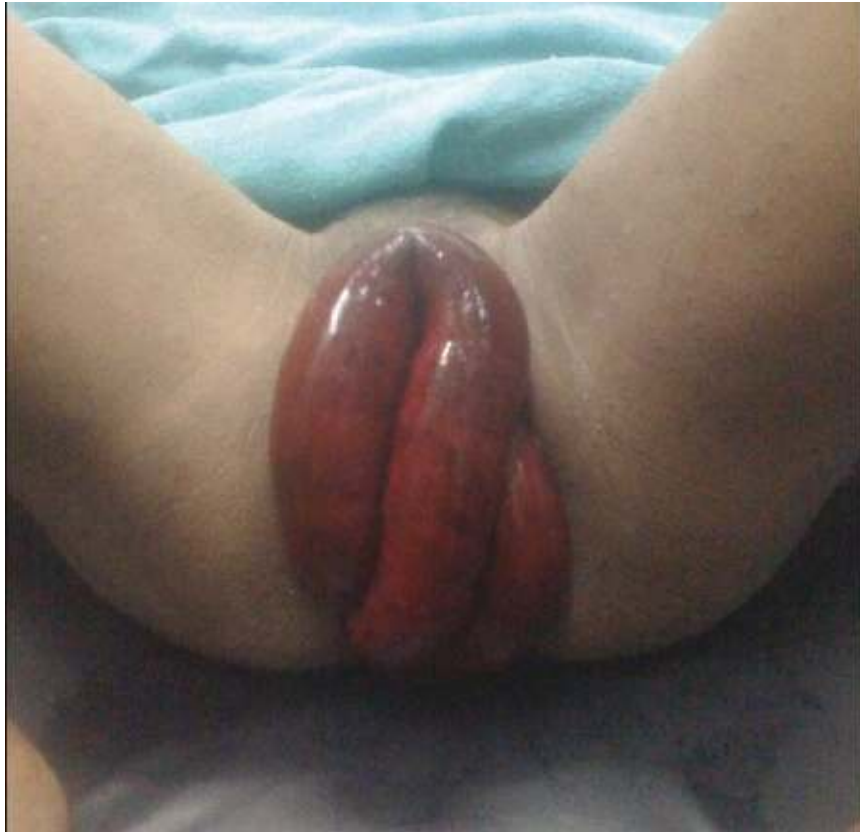

Fig. 3 Intraoperative photographs showing greater omentum incarcerated through the anterior wall defect of the uterus [59]

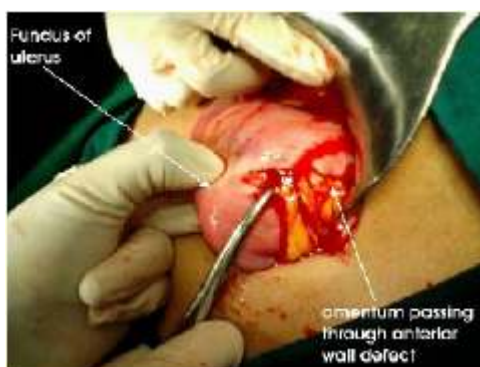

Fig. 4 Richter type hernia showing antimesenteric side of small bowel wall partially incarcerated in the uterine wall

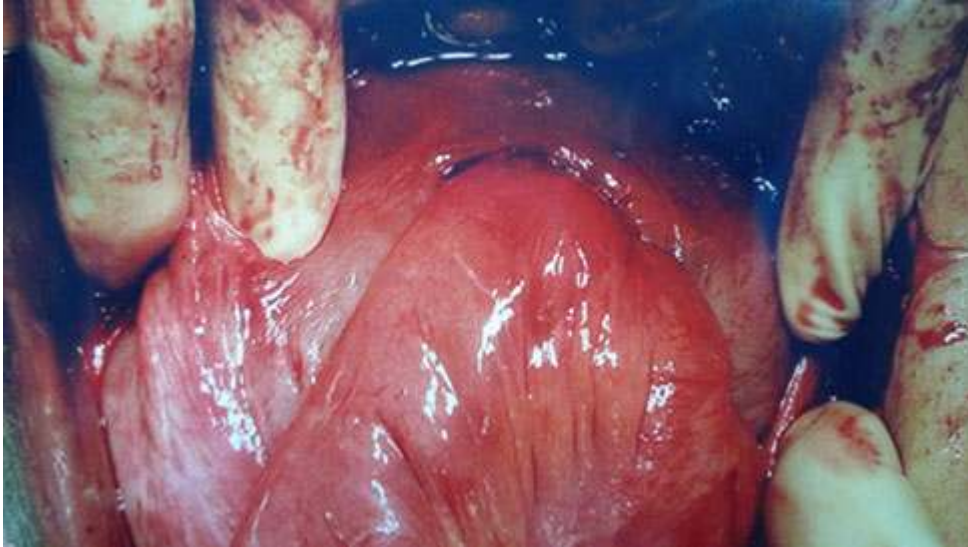


Fig. 5 a) and b) Transabdominal pelvic ultrasound images demonstrate a retroverted uterus (UT) adjacent to the urinary bladder (BL) with adjacent fluid filled small bowel (SB) closely apposed to an interrupted uterine wall (asterisk). A tubular structure is seen within the uterus. A small amount of anechoic free fluid (FF) is seen in the cul-de-sac. Linear echogenicity (arrow), consistent with the appearance of gas, is adjacent to the abnormal intrauterine tubular structure [47]

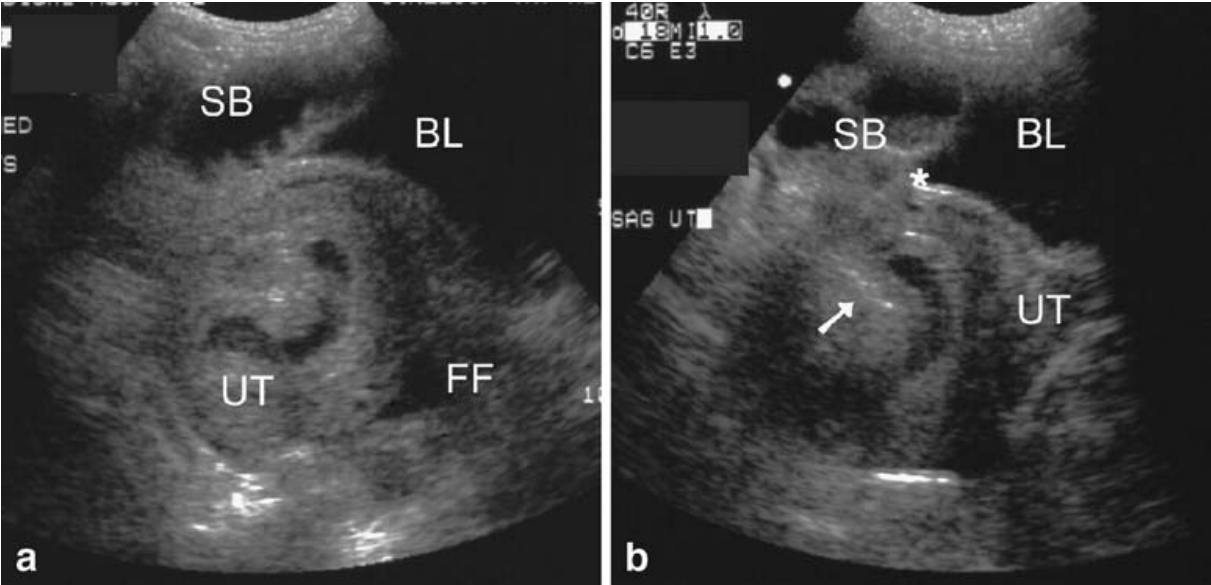


Fig. 6 Transvaginal pelvic ultrasound transversely demonstrates multiple tubular structures containing anechoic fluid within the uterine cavity (UT). Sagittally, echogenic material (arrowheads), suggesting the presence of fat, is adjacent to the intrauterine tubular structure [47]

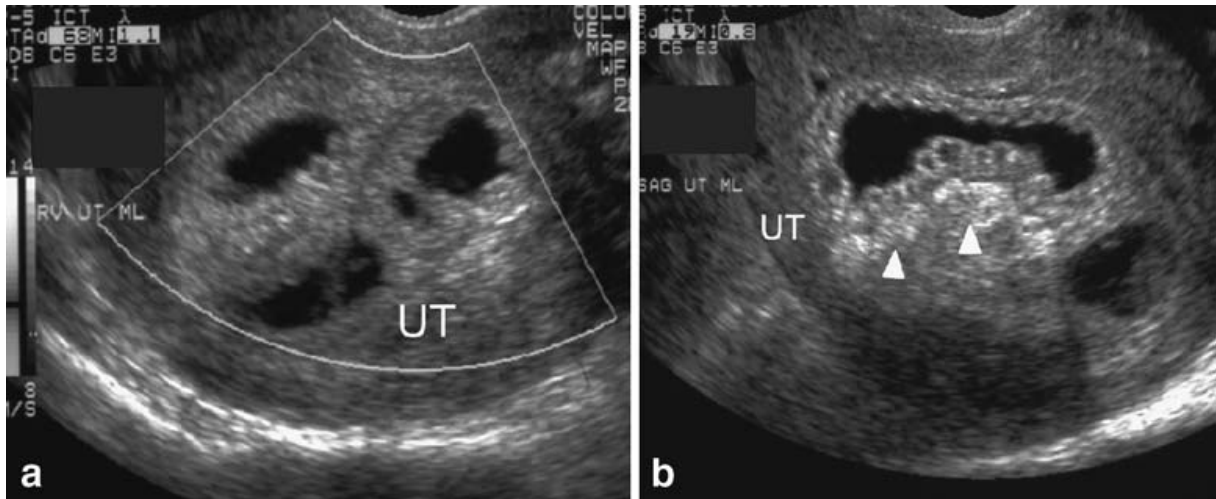


Fig. 7 Pelvic computed tomography scan taken after failure of conservative treatment.

Intrauterine mass was later shown to be an incarcerated bowel [33]

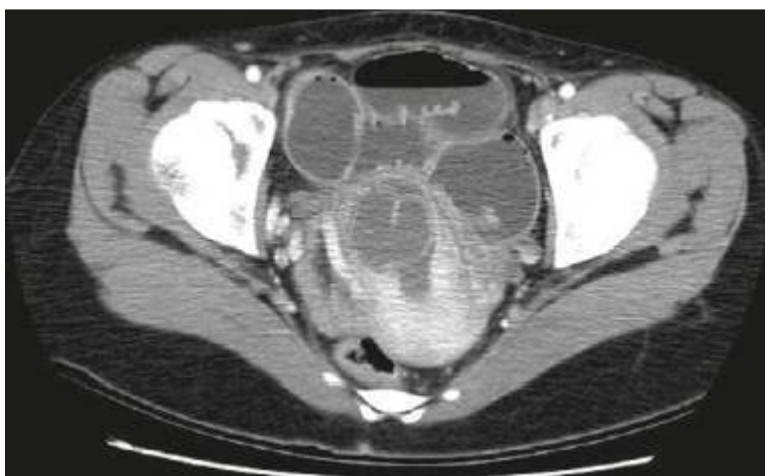

Table 2 MOOSE checklist for small bowel obstruction due to uterine perforation after surgical abortion

Criteria	Brief description of how the criteria were handled
Background	
Problem definition	Small bowel obstruction due to uterine perforation after surgical abortion is rare but potentially devastating event. There are no pathophysiologic mechanisms described and no diagnostic and therapeutic algorithms present on the subject
Hypothesis statement	Construction of diagnostic and therapeutic algorithms could increase maternal survival rate and minimize intraoperative and postoperative complications
Description of study outcomes	Incidence, risk factors, mechanisms of small bowel obstruction, clinical presentation, diagnosis, treatment and maternal outcome
Type of exposure or intervention used	Small bowel obstruction
Type of study designs used	We included available fulltext case reports.
Study population	We placed no restriction.
Search strategy	
Qualifications of searchers	The credentials of the three investigators GA, TL and MM are indicated in the author list
Search strategy, including time period included in the synthesis and keywords	PubMed from 1946 to 2012 PubMedCentral from 1900 to 2012
Databases and registries searched	PubMed and PubMedCentral
Search software used, name and version, including special features	We did not employ search software

Criteria	Brief description of how the criteria were handled
Use of hand searching	We did not use hand search
List of citations located and those excluded, including justifications	Only full text articles were included
Method of addressing articles published in languages other than English	We placed no restrictions on language; local scientists fluent in the original language of the article were contacted for translation
Method of handling abstracts and unpublished studies	We had contacted a few authors for unpublished studies on the association
Description of any contact with authors	We contacted authors of the articles that were not available in fulltext
Methods	
Description of relevance or appropriateness of studies assembled for assessing the hypothesis to be tested	Detailed inclusion and exclusion criteria were described in the Methods section
Rationale for the selection and coding of data	Data extracted from each of the studies were relevant to the population characteristics, study design, mechanisms, diagnostic modalities and therapeutic interventions and maternal outcome
Assessment of confounding	Possible confounding factor could be previous intraperitoneal surgery causing adhesions of small bowel to the uterus
Assessment of study quality, including blinding of quality assessors; stratification or regression on possible predictors of study results	Study quality is assessed by the comprehensiveness of the data in each case report
Assessment of heterogeneity	There was no heterogeneity of the studies due to case report nature of the studies
Description of statistical methods in sufficient detail to be replicated	Statistics is made only in percentages due to small sample

Criteria	Brief description of how the criteria were handled
Provision of appropriate tables and graphics	We included one table for MOOSE checklist, one table of all studies, four figures of small bowel obstruction mechanisms, two figures of pelvic ultrasound findings and one computed tomography scan of small bowel incarceration through uterine wall
Results	
Figures of small bowel mechanisms	Figures 1 - 4
Figures of pelvic ultrasound	Figures 5, 6
Figure of computed tomography scan	Figure 7
Table giving descriptive information for each study included	Table 1
Discussion	
Quantitative assessment of bias	Due to small number of studies assessment of bias could not be conducted
Justification for exclusion	We excluded studies with (1) complex injuries when small bowel incarceration was present but with bleeding and/or bowel perforation as the leading symptomatology, (2) uterine perforation after dilation and curettage after labor for any cause and (3) articles on the topic only numbering the patients without important data
Assessment of quality of included studies	All fulltext case reports on the subject were included
Conclusions	
Consideration of alternative explanations for observed results	Confounding factor could be previous intraperitoneal surgery causing adhesions between small bowel and uterus. We did not find such cases in our study
Generalization of the conclusions	One should be cautious with generalization because only half of published studies are analyzed and certainly there are cases without medical documentation especially in Africa

Criteria	Brief description of how the criteria were handled
	where this pathology is most common
Guidelines for future research	We recommend publishing of every case on the subject for construction of more precise diagnostic and therapeutic algorithms
Disclosure of funding source	No separate funding was necessary for the undertaking of this systematic review

Table 1 Characteristics of cases included regarding small bowel obstruction after uterine perforation due to surgical abortion

Reference	Age	Gravida/Para/ Abortion	Pregnancy duration	Abortion method	Risk factors	Duration of symptoms	Blood pressure	Pulse (min)	X-ray
Whitall 1911 [26]	23		4 months	Dilation and Currettage	Retained part of placenta 1 year ago	2 hours	Normal	Normal	No
Palmer 1923 [27]	28		8 weeks	Dilation and Currettage		5 days	Normal	96	No
Sarnoff 1923 [28]	26		10 weeks	Surgical	Unknown	1 hour	hypotensive	120	No
Wolff 1946 [29]	30								
Haddad 1949 [30]				Criminal		2 hours			
Cooke 1965 [37]	33	G3P3	10 weeks	Abortion	Abortion 6 months ago - no data	4 days	116/90	96	Yes
Shenoi 1966 [54]	23	G1P1	8 weeks	Criminal	No	30 hours	130/70	100	No
Dunner 1983 [46]			13 weeks	Suction	Cesarean section	1 hour			No
McArdle 1984 [52]	31	G2P?A2	8 weeks	Suction	No	24 hours	Normal	Normal	Yes
Leibner 1995 [12]	30	G3P1	< 12 weeks	Suction	No	22 days	130/70	68	Yes
Oludiran 2003 [57]						Less then 24 hours			No
Oludiran 2003 [57]						Less then 24 hours			No
Oludiran 2003 [57]						More then 48 hours			
Oludiran 2003 [57]						More then 48 hours			
Oludiran 2003 [57]						More then 48 hours			
Sherigar 2005 [53]	34	G6P5A0	12 weeks	Dilation and Currettage	No	2 hours	hypotensive	120	No
Shulman 2006 [47]	36	G9P6	9 weeks	Surgical	Unknown	2 days		85	No
Jhobta 2007 [6]			< 12 weeks	Abortion					
Jhobta 2007 [6]			< 12 weeks	Abortion					

Chang 2008 [33]	39	G3P2A1	7 weeks	Dilation and Currettage	Failed medical abortion / 2 previous cesarean sections	24 hours	Normal	Normal	Yes
Nkor 2009 [39]	36	G5P5	12 weeks	Abortion	No	4 months	Normal	Normal	Yes
Seow-En 2010 [36]	30	G2	34 weeks	None	Retained part of placenta 2 year ago	2 years	Normal	Normal	
Aworinde 2011 [58]	22	G2P2	12 weeks	Criminal	Unknown	10 hours	80/40	120	No
Gupta 2011 [55]	30	G7P6	14 weeks	Unsafe	Unknown	2 hours	80/50	146	No
Dossou 2012 [40]	18	G1P0	8 weeks	Abortion	Unknown	2 hours	90/50	120	No
Dossou 2012 [40]	30	G1P0		Dilation and Currettage	Unknown	24 hours	120/80	88	No
Coughlin 2012 [38]	21	G2P0A2	18 weeks	Dilation and Currettage	2 elective abortions	3 weeks	Normal	Normal	Yes
Lebeau 2012 [56]	25	G0P0	13 weeks	Criminal	No	12 hours	90/60	115	No
Aliyu year? [35]	25	G3P2A2	8 weeks	Surgical	Failed medical abortion	24 hours	90/60	104	No
Werelius 1907 [22]	20			Criminal		6 hours		90	No

Transabdominal Ultrasound	Transvaginal Ultrasound	CT scan	Mechanism of obstruction	Operative procedure	Site/size of uterine injury	Uterine injury treatment	Outcome
No	No	No	Vaginal evisceration	Resection (350 cm) with anastomosis	Fundus	Sutures	Survived
No	No	No	Vaginal evisceration	Resection (98 cm) with anastomosis	Fundus (2.5 cm)	Sutures	Survived
No	No	No	Vaginal evisceration	Resection (450 cm) with anastomosis	Anterior (2.5cm)	Hysterectomy	Survived
			Vaginal evisceration	Resection (150 cm)	3 cm		Survived
			Vaginal evisceration	Resection with anastomosis		Hysterectomy	Survived
No	No	No	Ileal adhesion	Adhesiolysis	Posterior (1.5 cm)	Hysterectomy	Survived
No	No	No	Vaginal evisceration	Resection (390 cm) with anastomosis	Fundus (3 cm)	Hysterectomy	Survived
		No	Bowel in uterine wall		Anterior		Survived
Yes	Yes	No	Bowel in uterine wall	Viable small bowel			Survived
No	No	No	Herniated omentum with stangulated small bowel	Resection (5 cm) with anastomosis	Two (1 cm) perforations	Not repaired	Survived
		No	Vaginal evisceration	Resection with anastomosis		Sutures	Survived
		No	Vaginal evisceration	Resection with anastomosis		Sutures	Survived
			Bowel in uterine wall	Resection with anastomosis		Sutures	Survived
			Bowel in uterine wall	Resection with anastomosis		Sutures	Survived
			Bowel in uterine wall	Resection with anastomosis		Sutures	Survived
No	No	No	Vaginal evisceration	Resection (400 cm) with anastomosis	Fundus	Sutures	Survived
Yes	Yes	No	Bowel in uterine wall	Resection (18 cm) with anastomosis			Survived
			Vaginal evisceration	Resection (anastomosis)	Fundus		Survived
			Vaginal evisceration	Resection (all small bowel) with stoma	Anterior or Fundus		Died

Yes	No	Yes	Bowel in uterine wall	Resection with anastomosis	Lower segment (cesarean section scar)	Sutures	Survived
Yes	Yes	No	Ileal adhesion	Resection (10 cm) with anastomosis	Fundus		Survived
			Richter type hernia	Adhesiolysis	Anterior (2 cm)	Sutures	Survived
No	No	No	Vaginal evisceration	Resection (200 cm) with anastomosis	Fundus (3 cm)	Sutures	Survived
No	No	No	Vaginal evisceration	Resection (100 cm) with anastomosis	Fundus	Sutures	Survived
No	No	No	Vaginal evisceration	Resection (200 cm) with anastomosis	Posterior	Sutures	Survived
No	No	No	Vaginal evisceration	Resection (200 cm) with anastomosis	Uterus (1 cm)	Sutures	Survived
Yes	Yes	Yes	Ileal adhesion	Resection (10 cm) with anastomosis	Fundus	Sutures	Survived
No	No	No	Vaginal evisceration	Resection (2.5m) with anastomosis	Fundus	Sutures	Survived
No	No	No	Vaginal evisceration	Resection (30 cm) with anastomosis	Posterior (4 cm)	Sutures	Died
No	No	No	Vaginal evisceration	Resection (365 cm) with anastomosis	Fundus	Sutures	Survived